Proceedings of the Australian Association of Neurologists

Vol. 1, No. 1
May, 1963

Published by
Australian Association of Neurologists

Editor:
E. GRAEME ROBERTSON

with the collaboration of
JOHN BILLINGS
GEORGE SELBY

Registered at the G.P.O., Melbourne, for transmission by post as a book
Printed in Australia by Brown, Prior, Anderson Pty. Ltd.

CONTENTS

Immunization against Poliomyelitis in Australia	*John Billings*	1
By-passing Vertebral Artery Occlusion by Extracranial Anastomotic Channels	*John A. Game*	5
Clinical Features of Obstruction of the Proximal Part of the Major Extracranial Arteries	*George Selby*	9
Progressive Multifocal Leuko-encephalopathy	*Mercy Sadka*	13
The Stiff Man Syndrome	*J. L. Allsop*	19
Some Aspects of Disseminated Sclerosis in Queensland	*P. J. Landy*	23
A Review of the Features and Treatment of Temporal Lobe Epilepsy, with special reference to Surgery	*Eric Davis*	27
Observations on the Prognostic Signs following Relief of Spinal Cord Compression	*Anthony Fisher*	31
Acute Encephalopathy in Childhood	*R. McD. Anderson*	35
Deep Sensibility	*A. K. McIntyre*	37
Cytogenetic Studies in Mental Retardation	*Brian Turner*	41
Psychotomimetics—A Neuropharmacological Study	*David R. Curtis*	43
Dystonic Seizures: Striatial or Extrapyramidal Epilepsy	*James W. Lance*	47
The Falling Attacks of Myoclonus	*James W. Lance*	49
Visual Mechanisms and the Electroencephalogram	*Ross Davis*	53
Further Observations of the Suprapineal Arachnoid Body	*G. C. T. Kenny*	57
The Problems of Subdural Gas after Pneumoencephalography	*E. Graeme Robertson*	61
List of Members		69

EDITORIAL

"Of making many books there is no end;
and much study is a weariness of the flesh."

FOR some time the question of producing an Australian neurological journal has been under consideration. It was realized that there was a plethora of journals—and we were unwilling at this stage to inflict another upon neurologists. Rather it was believed that the need existed to reduce the amount to be read by exacting selection and condensation. The practical difficulty of financing and gaining circulation for a new journal also acted as a deterrent. However, it seems desirable that Australian neurology should have some means of expression.

Therefore it was decided to publish a record of the proceedings of our yearly meeting which always seemed to us to be a stimulating and pleasant experience. In order to make the material free to those who wished to read, we decided to seek financial aid. This was very readily forthcoming for the Ciba Company, acting through its Medical Director in Australia, Dr. V. G. Balmer, generously undertook the expense of production and distribution of five hundred copies of the proceedings. The Australian Association of Neurologists wish to express their deepest gratitude to this Company, which asked for nothing in return, not even acknowledgment. It is intended to distribute the proceedings to members of our association, to libraries of universities and neurological hospitals, and to a number of neurologists elsewhere.

Every paper presented at the 1962 meeting is included.

Here, then, is this small publication! In return, we would be extremely grateful for evaluation and suggestions from recipients. Upon this may depend its continuance in the present form, its expansion into a more formal journal—or the termination of the project.

As this is the first publication of the Australian Association of Neurologists, a list of its members is appended. Nearly all have been associated with the National Hospital for Nervous Diseases, Queen Square, London, and most of the clinicians have been house-physicians at that Hospital. With this first publication we express our indebtedness to our teachers and hope that it illustrates the continuing influence of British Neurology.

33 Collins Street
Melbourne, C.1, Victoria, Australia

IMMUNIZATION AGAINST POLIOMYELITIS IN AUSTRALIA

JOHN BILLINGS
Melbourne

WHEN the Salk immunization campaign was commenced in Australia in 1956, the community was almost entirely free of the disease. This was extremely fortunate after the experiences with the Cutter vaccine in the United States of America; there some batches of vaccine had become contaminated with live virus and provoked poliomyelitis in a proportion of persons inoculated. Had any Australian been incubating the disease at the time of inoculation it would have been hard to disprove that the subsequent development of poliomyelitis was unrelated to the vaccine. In fact, there is no evidence that anyone in Australia has ever been inoculated with Salk vaccine accidentally containing live virus. Altogether over 6 million persons have been inoculated, about 80 per cent of whom have received a full course of three injections. About 18 million injections of the vaccine have been given altogether. There have been occasional reports of allergic reactions and skin rashes, the latter being usually attributed to the small amount of streptomycin in the vaccine. There are no substantial reports of any serious neurological sequelae, although there have been a few instances of painful stiffness of the arm and shoulder, resolving within the following months. Australians generally have always been most co-operative in reporting any symptom which has appeared within months, or even years, of medical treatment. The dearth of evidence of mishap in the campaign against poliomyelitis in Australia indicates, therefore, that Salk vaccine is one of the most trouble-free immunizing agents ever used.

Analysis of the results indicates that the degree of protection afforded by the Salk vaccine is extremely high and approximates to 95 per cent. When poliomyelitis has occurred in vaccinated individuals the case histories show the same distribution with regard to sites of paralysis and severity as in unvaccinated individuals. There has been no relationship between the placement of the injection and the location of the paralysis arising from the disease.

It has been suspected that the Salk vaccine which has been used in Australia has been least effective against type 3 polio virus and it is now recommended that a fourth dose be given.

The initial injection of the vaccine induces a "sensitive" state which persits for several months. The administration of the second injection more than two weeks later produces further antibody rise or converts those who had a negative antibody response to the first injection to positive. The administration of the second dose of vaccine four to five months after the first, produces a similar or even better effect than when the interval is only one month.

About a month after the administration of the second dose a "hypersensitive" state commences, and increases up to about the sixth month, so that the maximal benefit from the third injection is obtained when it is given at or after a period of six months from the second injection.

Although the Salk vaccine is so effective in conferring immunity from systemic infection with the virus, it does not prevent it multiplying in the gut, and therefore it permits the virus to continue circulating in the community.

The Enteroviruses

In addition to the polioviruses there are 58 serological types of other enteroviruses known at present, subdivided into Coxsackie group A, Coxsackie group B and Echo viruses. All the enteroviruses multiply in the human alimentary tract and are excreted in the faeces. Viruses of the coxsackie A group may cause Herpangina, of the coxsackie group B may cause Pleurodynia and Neonatal Myocarditis, whilst echo viruses may cause summer diarrhoea. Some of these other enteroviruses share with the polioviruses the ability to invade the central nervous system, and do so in a proportion of cases of infection. The most common manifestation of this involve-

ment is benign aseptic meningitis. Epidemics of aseptic meningitis of this character have been described, particularly due to coxsackie group B and echo viruses.

Occasional cases of infection by enteroviruses other than the poliovirus may be accompanied by muscular paralysis, and this has been reported in infections with coxsackie group A (types 4, 7 and 9), coxsackie group B (types 2, 3, 4 and 5) and echo virus (types 2, 4, 6, 9, 11, 16 and the Frater virus). Improved virus isolation techniques and progressive elimination of poliomyelitis by vaccination have combined to establish these other viruses as causes of paralysis in humans. Many of the enteroviruses are highly infectious and are widely distributed during epidemic periods, so that they can often be isolated from apparently healthy persons. It is, therefore, difficult to determine in a particular case whether such a virus is truly the cause of the patient's illness; the etiological connection, however, is verified by the isolation of the virus from the central nervous system of fatal cases. In less severe cases of suspected infection, isolation of the virus from the throat or from faeces is not so convincing as isolation from the cerebro-spinal fluid.

So far as Victorian experience is concerned, it has not been firmly established that any enterovirus other than poliovirus has caused serious muscular paralysis. There has however, been a report incriminating the coxsackie A4 virus as the cause of one case of paralysis in Australia (Duxubry 1961).

It is remembered that certain viruses other than enteroviruses may cause illness resembling paralytic poliomyelitis in humans; these include mumps, herpes simplex, herpes zoster and certain arbor viruses.

The Vacuolating Virus

The SV40 virus, also known as the vacuolating virus, because of the vacuoles which may appear in the cells of the tissue used for its culture, was detected many years ago in preparations of attenuated poliovirus. The SV40 virus is not uncommon in cells of monkey origin. The virus had been responsible for some opposition to the use of attenuated poliovirus in place of the Salk vaccine but it was later shown that many batches of the Salk vaccine also contained SV40 virus and that this virus was not always killed by the formalinization process used in the manufacture of the Salk vaccine. Indeed, many millions of humans have now been inoculated acidentally with the SV40 virus as a contaminant of either a Salk type of poliovirus vaccine or of an attenuated live poliovirus vaccine. Fortunately this inoculation does not appear to have produced any harmful affects whatsoever.

A disturbing report was that of Bernice Eddy (Eddy et alii, 1961) on neoplasms which appeared in hamsters following inoculation with monkey kidney cell extract. In 109 out of 154 new born hamsters, tumours developed some months later at the site of injection. These experimental results have been confirmed and in one instance the vacuolating virus was isolated from the tumour tissue. This may of course have been a contaminant but it is somewhat surprising that this work has not caused greater concern.

In the preparation of poliovirus vaccine the vacuolating virus escaped detection for a long time because it does not produce obvious lesions in the kidney cell cultures prepared from the African Green Monkey. When cultures of kidney cells from the Rhesus Monkey are employed the virus is readily detected.

Live Vaccine

It is particularly in the preparation of live virus vaccines that there has been concern regarding the possibility of contamination by dangerous Simian viruses, especially the vicious Simian B virus (Sabin) which can cause fatal encephalitis in monkeys. There has been an effort made to find a substitute for monkey kidney in vaccine production and recently a human foetal cell line has been developed. In addition newer methods of inactivating some of the extraneous viruses in the live vaccine have been evolved.

The other fear with regard to live virus vaccine has been the possibility that the virus may regain its wild virulence. There have been reports of genetically different types developing from attenuated virus both in tissue culture and as the result of human passage. In addition there has been some evidence to suggest that

a few human cases of poliomyelitis have resulted from use of supposedly attenuated strain of type 3. A number of genetic markers have been defined and these are believed to be associated with lack of virulence; there seems, for example, to be a close correlation between the ability of type 1 virus to develop at a high temperature (40-41°C.), and its neuro-virulence.

One of the outstanding advantages of the oral vaccine is that the attenuated virus will spread throughout the community in the same way as poliomyelitis and the other enterovirus infections, so that the reservoir of unvaccinated persons will eventually be contaminated and rendered immune.

Live vaccines are cheaper and easier to administer and can be used to halt epidemics because they induce immunity quickly. The production of local gut immunity in addition to humoral immunity prevents the immunized individual acting as a carrier of the wild virus.

A successful vaccine should have high infectivity so that it will readily establish itself. It was previously thought desirable that it should not produce viraemia, but it has been shown that viraemia commonly occurs and does not appear to be harmful. The vaccine must be shown to be free of harmful effects upon the foetus in utero.

Extensive trials of the live vaccine have involved the administration of more than 200 million does with excellent results; the vaccine most used in the United States of America and also in Russia has been that of Sabin, whilst two other American oral vaccines have also been widely used, that of Koprowski in Poland, and that of Cox in the United States of America and also in Latin America.

The Interference Phenomenon

When any one of the enteroviruses is present in the intestine it is difficult for another of them to became established there. Type 2 poliovirus resists interference whereas type 1 is most susceptible to suppression by other enteroviruses. If there is a high incidence of enterovirus infection in the community the trivalent live virus vaccine is prefered to the monovalent variety, because type 2 poliovirus will interfere with any other enteroviruses present coincidentally in the intestine. In six weeks time a second dose of the trivalent vaccine is given and now type 1 and type 3 virus will be more certain of provoking immunity.

In other circumstances the monovalent vaccine is used with an interval of not less than six weeks between the administration of each type and finally a dose of trivalent vaccine completes the immunizing programme, ensuring a double chance for each virus type to provoke immunity.

Maternal antibodies against poliomyelitis may prevent a good response to the Salk vaccine before the age of six months; the effectiveness of the oral vaccine is, however, not reduced by the maternal antibodies. In using the Sabin vaccine, for example, a dose of type 1 virus could be administered at eight weeks of age with the first dose of Triple Antigen. Six weeks later type 3 virus could be given with a second dose of Triple Antigen and after another six weeks type 2 virus with the third dose of Triple Antigen. At ten months of age the final dose of trivalent vaccine would be employed. This procedure could be expected to produce prolonged, and even life-long immunity, in almost 100 per cent of cases.

Acknowledgements

I am very much indebted to Dr J. S. Graydon of the Commonwealth Serum Laboratores, Melbourne, for information regarding the Salk vaccine campaign in Australia in all its details.

Dr A. A. Ferris, Microbiologist to the Fairfield Hospital, Melbourne, has answered my many questions with inexhaustible courtesy.

References

DUXBURY, A. E., WHITE, J., LIPSCOMB, B. M., and WILLIAMSON, W. S. (1961). "Illness Simulating Paralytic Poliomyelitis Associated with Coxsackie Group A, Type 4 Virus Infection." *Med. J. Aust.*, 2, 708.

EDDY, BERNICE E., BORMAN, G. S., BERKELEY, W. H., and YOUNG, R. D. (1961). "Tumors Induced in Hamsters by Injection of Rhesus Monkey Cell Extract." *Proc. Soc. Exp. Biol. and Med.*, 107, 191.

BY-PASSING VERTEBRAL ARTERY OCCLUSION BY EXTRACRANIAL ANASTOMOTIC CHANNELS

JOHN A. GAME
Melbourne

So much has been said and written about cerebralvascular disease in the last few years that one hesitates to try to add any more.

The changed orientation towards this subject has now reached the stage of being common knowledge. The altered concepts are probably due to the retarded realization of two basic factors. The first is the understanding of the frequency with which infarction is attributable to occlusion or partial occlusion of major vessels outside the skull. The second is the realization of the importance of colateral channels of circulation.

This altered outlook suggests that more may be gained if we approach our cases on the basis that in the normal healthy state obstruction of a single cerebral vessel will not cause any infarction (Denny-Brown). The capacity of the Circle of Willis, the surface network and the junctions between internal and external carotid systems are all now fairly well understood. Knowledge is still deficient on the question of anastomoses between the surface vessels of the cortex and the perforating vessels of the white matter and between the various branches of the basilar artery.

It is not my intention to dwell on these matters or any other aspects of this subject which have been so well elucidated in recent years. I thought it may however be of interest to draw attention to some observations which we have made, in conjunction with Dr Luke, in some cases of occlusion of the vertebral artery. The clinical histories of these patients is perhaps not of great relevance to the observations, but will be stated briefly to give some information of the life histories of the illnesses from which these patients suffered.

CASE I. Mrs M.K., a woman aged 44, was regarded as suffering from Ménierè's Syndrome. She had a history of a right mastoid operation 40 years earlier and for 14 months had had attacks of giddiness, tinnitus and increasing deafness in the right ear. There were no objective neurological signs and a right labyrinthectomy was performed. Her turns persisted and one was observed in neurological consultation. The patient was conscious and could open her mouth on request and protrude her tongue, but she could not speak nor move her limbs; her plantar responses were flexor. These episodes, which lasted for as long as 2 hours and had been occurring sometimes two or three times a day, had been regarded as hysterical.

Right vertebral angiography by Dr Luke, using the Seldinger catheter technique through puncture of the right branchial artery was normal, with a little reflux filling from the basilar artery into the left vertebral artery.

An attempt at left vertebral angiography by Seldinger catheter via the right femoral artery and aorta into the left subclavian provided good filling of the subclavian artery, the internal mammary artery, the thyro-cervical trunk and the costo-cervical trunk, but no filling of the left vertebral.

A later film of the same injection showed a clear blush in the thyroid gland and a continuous stream of blood through the ascending cervical branch of the thyro-cervical trunk to join and fill the vertebral artery at the level of the second cervical vertebra (Fig. 1). The vertebral artery at this level appeared to be of normal lumen.

On this basis it was considered unlikely that the more proximal portions of the vertebral artery were congenitally absent. It was thought that this flow through the ascending cervical artery represented a compensatory anastomosis by-passing an occluded vertebral artery.

CASE II. Mrs D.P. was a woman of 58. Two years previously she had had an episode of aphasia and weakness of the right arm which improved in a few weeks. Four months previously she had collapsed one day on return from her shopping; she felt giddy, fell to the floor and apparently lost consciousness. She then noticed a weakness of her right hand followed by weakness in both legs. Associated with this was a severe general headache, worse at the back of the head; this lasted for about two weeks. She also noticed pins and needles in both hands. She felt she had improved a little since the onset of these symptoms.

On examination she was an apparently fit woman with a blood pressure of 160/80. There was decreased hearing in the right ear and inco-ordination of the limbs, greater on the left. All deep reflexes were increased, the abdominal reflexes were absent and

FIG. 1A

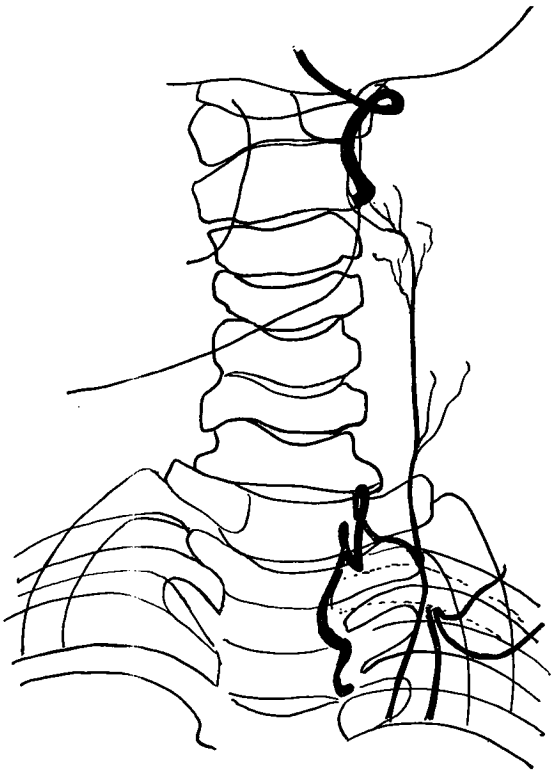

FIG. 1B

FIG. 1—CASE I. Only the distal part of the left vertebral artery is seen, the remainder of the artery being blocked down to its origin. The distal portion fills via ascending cervical branches of the thyro-cervical trunk.

plantar responses extensor, with clonus of both ankles. Sensation was normal.

Lumbar Puncture was normal. Left Vertebral Angiography indicated occlusion of the maor part of the vertebral artery but a relatively dense anastomotic network fed into the upper cervical portion of the artery.

Right Vertebral Angiography was attempted, but failed.

CASE III. Mr V.B. is probably the most interesting we have had. He was brought to the Casualty Department of the Alfred Hospital, having felt weak and begun to perspire profusely whilst driving a crane. He had an intense occipital headache with nausea and became stuperose when he reached the Casualty Department. Ninety minutes later he was fully conscious with severe occipital headache and vomiting. After four hours he had recovered completely and gave a history of three previous severe headaches—frontal and occipital—with sweating, vomiting and double vision. They had been regarded as "ophthalmoplegic migraine".

The Casualty staff were about to let him go home when he developed a right sixth cranial nerve palsy. Headache and vomiting recurred and he was admitted and soon became very drowsy and developed slurred speech. He had nystagmus, inability to adduct his eyes, left hemiparesis and defective motor function of his right fifth cranial nerve.

Lumbar puncture showed no abnormality but his deteriorating conscious state caused concern. In view of his history of "ophthalmoplegic migraine" we decided to wait and see, and after about six hours his physical signs recovered and the next morning he was quite well except for some residual occipital headache. His improvement continued and we decided to investigate him in the hope that we may learn something of "ophthalmoplegic migraine". Angiography by Seldinger catheter showed complete absence of the left vertebral artery, but good filling of the thyro-cervical trunk, costo-cervical trunk and internal mammary arteries. A second film of the same injection a few seconds later showed filling of the distal portion of the vertebral artery in the upper cervical region through the ascending cervical artery (Fig. 2).

The next day the right vertebral was studied and showed no filling of the origin of the right vertebral

FIG. 2A

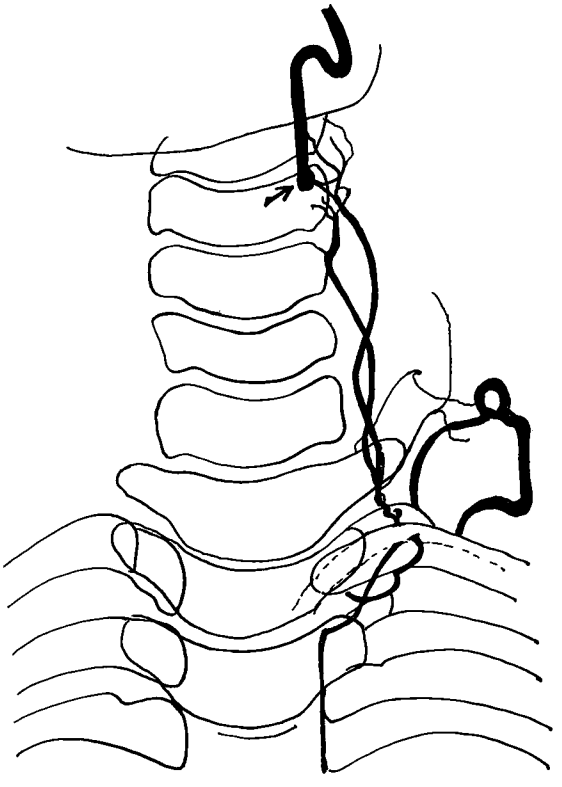

FIG. 2B

FIG. 2—CASE III. The proximal portion of the left vertebral artery is oblitered, and again a collateral influx occurs into the distal part of the artery.

artery and defective filling of its mid-cervical segments, but again apparently adequate filling of the upper cervical portion of the artery through the ascending cervical artery (Fig. 3).

We contemplated completing the study by angiography of his carotid arteries, but it was considered unjustifiable to submit this patient to the risk of any further investigation. He was seen several months later and remained in good health with no neurological signs.

The angiographic findings suggest that his recovery could be due at least in part to the development of the collateral circulation, although of course it is realized that we had not shown to what extent the basilar system was filled from the carotids.

The demonstration of these collateral channels filling the distal segments of occluded vertebral arteries is probably only a very small facet of the overall problem, but it has aroused my interest for two reasons.

First, it has seemed to me strange that whereas nature has so abundantly provided us with what may be called reserve physiological mechanisms, as for example the Circle of Willis and the surface anastomosis of the brain, when it comes to the brain stem, wherein reside what we commonly call the vital centres, we have only one basilar artery, the occlusion of which may be catastrophic.

Yet, paradoxically, Marshall and Shaw have produced figures showing us that occlusive vascular disease of the brain stem carries with it a better prognosis than cerebral infarction. This is a fact which perhaps we have all observed for ourselves.

The reason is not clear to me, but it must suggest that there is in fact a degree of anastomosis which can compensate for the occlusion of a basilar artery. Meyer, Sheehan and Bauer of Detroit have in fact produced some angiographic evidence that this is so.

The second reason for my interest is that we

FIG. 3A

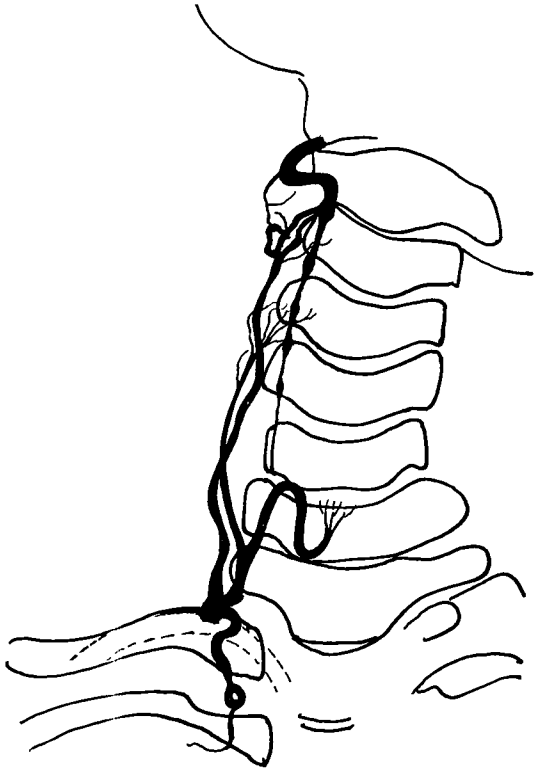

FIG. 3B

FIG. 3—CASE III. A similar condition is shown on the right side.

have not seen any reference elsewhere to this by-passing of an occluded vertebral artery by these extra-cranial anastomotic channels. This may be only a very small thread in the total fabric of knowledge of cerebral vascular disease which is being woven, but it does seem to provide a fundamental thread in our understanding of the life history of vertebro-basilar occlusion and help to explain the statistical observation of Marshall and Shaw that the prognosis in these cases is better than has been generally believed in the past. It will be noted that the three cases shown are still alive and reasonably well.

Also, one of the cases may provide some clue to our understanding of the obscure syndrome which is, perhaps, euphemistically labelled "ophthalmoplegic migraine".

References

DENNY-BROWN, D. (1960). Recurrent cerebrovascular episodes. *Arch. Neurol.* (*Chic.*), **2**, 194.

MARSHALL, J., and SHAW, D. A. (1959). Antigoagulant therapy in cerebrovascular disease. *Proc. Roy. Soc. Med.*, **52**, 547.

MEYER, J. S., SHEEHAN, S., and BAUER, R. B. (1960). An arteriographic study of cerebrovascular disease in man. I. Stenosis and occlusion of the vertebral-basilar arterial system. *Arch. Neurol.* (*Chic.*), **2**, 27.

CLINICAL FEATURES OF OBSTRUCTION OF THE PROXIMAL PART OF THE MAJOR EXTRACRANIAL ARTERIES

GEORGE SELBY
Sydney

THE clinical picture of stenosis or occlusion of the internal carotid artery is now well recognized. The pathological studies of Yates and Hutchinson (1961) have confirmed that narrowing and occlusion of the extracranial cerebral arteries is found at post mortem in many elderly patients without demonstrable infarcts of the brain. They concluded that cerebral infarction is usually the result of a combination of systemic disease and stenosis of the intracranial or extracranial vessels, the latter being more frequently involved. In the majority of their cases more than one major extracranial artery was severely affected. The most common site of stenosis of the vertebral artery is in the first 2 centimetres from its origin from the subclavian artery, while in the carotid artery the sinus is usually the site of the disease.

During the last five years several reports have appeared in the literature (Rob and Wheeler, 1957; DeBakey *et al.*, 1959; Crawford *et al.*, 1959; Bernatz, 1960; Ellis, 1960), which discuss the merits of surgical treatment for localized stenotic or occlusive disease in patients with intermittent focal ischaemic cerebral vascular attacks. From a study of the pathological data provided by Yates and Hutchinson (1961), it is obviously important to demonstrate the entire course of the extracranial cerebral arteries by angiography before any consideration to reconstructive surgery can be given.

The development of an angiographic technique where the radio-opaque dye is injected near the arch of the aorta through a catheter inserted into the femoral artery (Seldinger, 1953) has enabled us to demonstrate partial and complete occlusions of the major extracranial vessels near their origin.

The indications for angiography are limited to patients in whom the diagnosis may be in doubt, or where the clinical picture suggests a localized obstruction of an extracranial artery which could be treated surgically. The clinician may then be faced with a decision between total angiography and the simpler percutaneous method, which will demonstrate the state of the vessel only beyond the site of insertion of the needle.

A review of the clinical presentation of four patients with proximal obstructive lesions revealed features which may assist in this decision. It is recognized that a valid indication for angiography was present in only two of the four patients to be presented (Cases III and IV). The age and general condition of the other two patients precluded any surgical intervention. The motives for total angiography were a desire to test the scope and limitations of this method, and curiosity to confirm the clinical diagnosis of multiple extracranial arterial disease.

CASE I. A man, aged 62 years, complained of recurrent brief episodes of giddiness and ataxia, accompanied by diplopia and blurring of vision. These had occurred several times each week during a period of three months. Attacks of twitching of the left side of his face were observed by his son. The history suggested an insufficient circulation through both the basilar and right internal carotid arteries. Examination revealed no abnormality apart from a bruit audible over the left orbit. The blood pressure was 160/90 in each arm. Arteriograms obtained by femoral catheterization (Fig. 4) show absence of filling of both vertebral arteries. A percutaneous right carotid angiogram revealed narrowing of the terminal part of the internal carotid artery. Percutaneous injection of the dye into the left carotid artery resulted in simultaneous filling of the carotid and basilar arteries, indicating that the circulation to the posterior fossa is derived entirely from the left internal carotid artery. This patient was treated with anticoagulants and had no further focal ischaemic attacks during the last 18 months. While curiosity was the main reason for total angiography in this case, the findings confirmed the clinical impression of both vertebral and carotid disease and supported the indications for anticoagulant therapy.

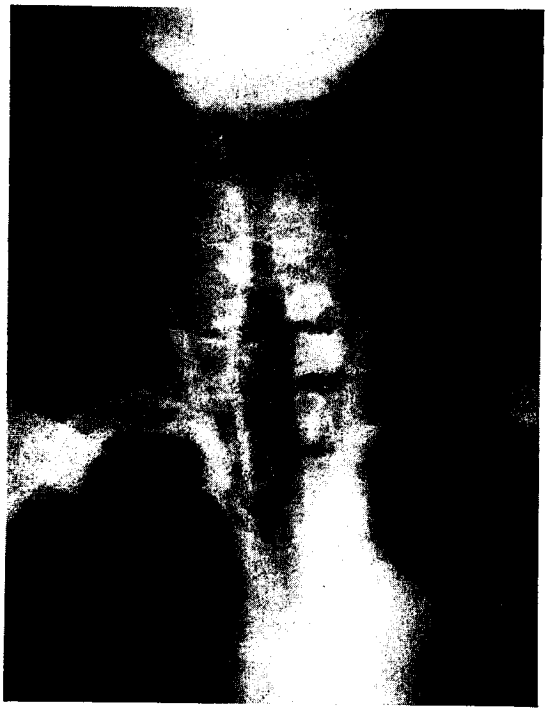

FIG. 4—Trans-femoral arteriogram of Case I, showing absence of filling of both vertebral arteries, while the subclavian, innominate, carotid, and internal mammary arteries are well outlined by the contrast medium.

CASE II. A man of 55 years had been subject to intermittent attacks of dysphasia, right hemiparesis and numbness of the right half of the body since 1958. He always recovered fully within 5 to 20 minutes. In June 1960 he suffered a left hemiplegia from which he recovered after 48 hours. Four weeks later a further sudden left hemiplegia occurred and persisted. Examination showed also a left hemianopia and hemianaesthesia as well as other signs of an extensive lesion of the right parietal lobe. No pulsation was palpable from the right carotid artery. The blood pressure in the left arm was 115/80, and in the right arm 80/60. Trans-femoral aortograms (Fig. 5) showed a stenosis of the innominate artery near the origin of the right subclavian artery. The right common carotid artery was narrow and the right internal carotid artery was completely occluded. The lumen of the left internal carotid artery was narrow and irregular. Anticoagulant treatment prevented further episodes of left carotid insufficiency, but he made only a partial recovery from the left hemiplegia. While the diagnosis was obvious from the clinical picture, the involvement of both carotid arteries, and the unequal blood pressures recorded from the two arms suggested that this patient presented a suitable problem to test the information obtainable from trans-femoral angiography.

CASE III. A woman of 46 years gave a history of transient episodes of blindness, dysphasia and paraesthesiae of the right side of the face since 1957. In June 1958, during an attack of paroxysmal tachycardia, she had a major epileptic seizure which was followed by a post-ictal right hemiparesis. During the next two years she complained of momentary feelings of unreality associated with an olfactory hallucination and followed by a transient weakness of the right limbs. At the age of 42 years she suffered a coronary occlusion, and two years later she developed intermittent claudication of the left leg. Neurological examination in June 1960 revealed no abnormality apart from a loud bruit audible over the right orbit. No arterial pulsation was palpable from the left side of the neck. The blood pressure in the right arm was 180/100,

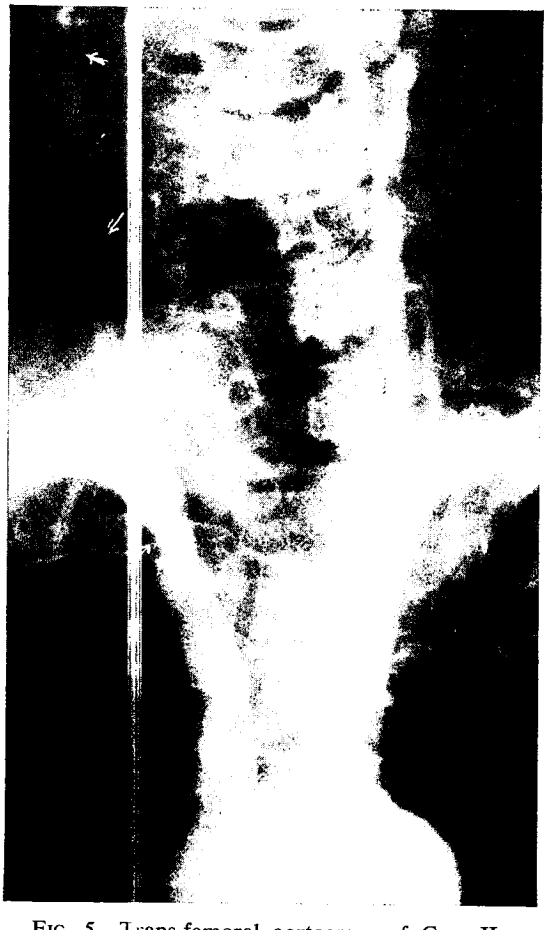

FIG. 5—Trans-femoral aortogram of Case II, showing stenosis of the innominate artery near the origin of the right subclavian artery. The right common carotid artery is narrow and the right internal carotid artery is completely occluded. The lumen of the left internal carotid artery is irregular.

FIG. 6—Trans-femoral arteriogram of Case III, demonstrating complete obstruction of the left common carotid artery at its origin with an extensive collateral circulation through the thyro-cervical trunk from the subclavian to the external carotid artery.

and in the left arm 125/100. Trans-femoral arteriograms (Fig. 6) show a complete obstruction of the left common carotid artery at its origin, and demonstrate an extensive collateral circulation through the thyro-cervical trunk from the subclavian to the external carotid artery.

As this patient was very distressed by the symptoms of her left carotid insufficiency, an attempt was made to by-pass the occluded common carotid artery by a graft from the subclavian artery to the internal carotid artery, which open exploration had shown to be patent. At operation, however, the brittle and sclerotic subclavian artery was found unsuitable for such a procedure. She was subsequently treated with anticoagulants and during the last 18 months complained only of occasional momentary temporal lobe attacks, but had no further major seizures nor episodes of blindness and hemiparesis.

CASE IV. A man, aged 51 years, suddenly became confused and dysphasic and lost the use of his right limbs in December 1961. After a few days his speech and right hemiplegia improved, but he continued to complain of diplopia, inco-ordination of the right arm and leg, and numbness of the right half of his body. Examination showed a right homonymous hemianopia, hemiparesis and hemianaesthesia, as well as a paresis of the superior rectus muscle of the right eye and a rotary nystagmus on upward gaze. Cerebellar ataxia of the right limbs remained after recovery from the hemiparesis. No intracranial bruit was heard. Carotid pulsation was palpable on both sides of the neck. The blood pressure in the right arm was 140/88, and in the left arm 90/60. He had complained of praecordial pain and of intermittent claudication in both legs for several years, and suffered a cardiac infarction two weeks after his cerebral vascular accident. In March 1962 his speech and the weakness and sensory impairment of the right half of the body had recovered completely, but the right hemianopia, a slight squint, and some cerebellar inco-ordination of the right limbs remained. The blood pressure was then 140/85 in each arm. As this man was relatively young, trans-femoral arteriograms were done to ascertain if he could be protected from further strokes by surgical correction of a localized stenotic lesion. The films showed that the vertebral and carotid arteries on both sides were patent and of normal calibre. It is thought, therefore, that his symptoms of vascular insufficiency, which involved both the left cerebral hemisphere and brain stem, may have resulted from emboli detached from a mural thrombus in the heart. The marked reduction of blood pressure in the left arm, recorded at the first examination, cannot be explained easily. He was treated with anticoagulants and had no further symptoms of cerebral vascular insufficiency during the last six months.

COMMENT AND CONCLUSIONS

A confident clinical diagnosis of occlusive cerebral arterial disease can be made from a careful history and examination in the majority of cases. Arteriography carries a small but definite risk, and is recommended only if diagnostic confirmation is required to decide on the need for anticoagulant therapy, or if the clinical status and age of the patient suggest that he may be a suitable candidate for surgical intervention. Provided that these criteria are fulfilled, the following clinical features are considered to be an indication for total angiography.

1. A history of involvement of both carotid arteries, or of both the carotid and vertebro-basilar systems.
2. An inequality of the blood pressure recorded from the two arms.
3. Complete absence of palpable carotid pulsation one one side of the neck.
4. In view of the possibility of involvement of several vessels, the entire course of the carotid and vertebral arteries from their origin

should be radiologically demonstrated before a decision in favour of reconstructive surgery is made.

Acknowledgement

My thanks are due to the staff of the Radiology Department of the Royal North Shore Hospital of Sydney, who performed the transfemoral Arteriograms.

References

BERNATZ, P. E. (1960). Surgical technics. *Proc. Mayo Clin.*, **35**, 487.

CRAWFORD, E. S., DEBAKEY, M. E., FIELDS, W. S., COOLEY, D. A., and MORRIS, G. C., Jr. (1959). Surgical treatment of atherosclerotic occlusive lesions in patients with cerebral arterial insufficiency. *Circulation*, **20**, 168.

DEBAKEY, M. E., CRAWFORD, E. S., COOLEY, D. A., and MORRIS, G. C., Jr. (1959). Surgical considerations of occlusive disease of innominate, carotid, subclavian and vertebral arteries. *Ann. Surg.*, **149**, 690.

ELLIS, F. H., Jr. (1960). Results of surgical treatment. *Proc. Mayo Clin.*, **35**, 492.

ROB, C., and WHEELER, E. B. (1957). Thrombosis of internal carotid artery treated by arterial surgery. *Brit. med. J.*, **2**, 264.

SELDINGER, S. I. (1953). Catheter replacement of the needle in percutaneous arteriography. *Acta radiol. (Stockh.)*, **39**, 368.

YATES, P. O., and HUTCHINSON, E. C. (1961). Cerebral infarction: the role of stenosis of the extracranial cerebral arteries. *Spec. Rep. Ser. med. Res. Counc. (Lond.)*, No. 300.

PROGRESSIVE MULTIFOCAL LEUKO-ENCEPHALOPATHY

A case studied clinically and pathologically

MERCY SADKA
Perth

I SHOULD say at the outset that this is, in effect, a single case report, and, furthermore, one that has been reported in part already (Richardson). However, the number of cases of progressive multifocal-leukoencephalopathy which have been reported or are known to be in the process of publication totals only 24, and this is the first Australian example.

Attention was first drawn to this condition by Aström, Mancall and Richardson in 1958, when they reported three cases of a cerebral demyelination disorder in association with chronic lymphatic leukaemia and Hodgkin's disease. They found five additional cases in the literature which they thought demonstrated the same pathological features, two in cases of Hodgkin's disease, one in sarcoidosis and one in a case of tuberculosis. All other cases hitherto described have also been associated with lymphomas and leukaemias except for a further case with sarcoid, two cases with carcinomatosis, and two where no association with a particular disease entity is mentioned. There is nothing about the associated diseases which marks them as being different from other diseases in a similar category without this complication.

The clinical course in progressive multifocal leuko-encephalopathy comprises a relentless deterioration of cerebral function, fatal after a period of months, with manifestations of widespread but generally asymmetrical disorder. Except for a moderate lymphocytosis in two cases, the cerebrospinal fluid has been normal whenever it has been examined. In the few cases where carotid angiography or air encephalography have been performed, these contrast X-ray studies have been normal. The electroencephalogram in cases in which it has been done has been diffusely and asymmetrically abnormal.

The pathological lesions have been correspondingly widespread and quite characteristic. They comprise small patchy and larger confluent areas of demyelination, with preservation of axis cylinders, situated predominantly in the cerebral hemispheres, but often, though not in our case, in the brain stem and cerebellum also. The demyelination is associated with remarkable cellular changes not seen in any other disease. The lesions are often peri-vascular, but not predominantly so. Peri-vascular lymphocytic infiltrations, so often seen where neurological complications of the lymphomas and leukaemias occur, are, with rare exceptions, minimal or absent here. They were not seen in our case. The myelin breakdown products are sudanophilic and the lesions contain numerous macrophages filled with this material. The astrocytes show bizarre hyperplastic changes, some being of giant size, some multi-nucleated and some containing mitotic figures. However this alteration is now known not to be seen in all cases, though they are well marked in ours, and were, in the first report, strongly emphasized. On the other hand an invariable change appears to be in the oligodendrocytes which exhibit enlargement with dense basophilia and loss of nuclear detail, and very frequently eosinophilic intranuclear inclusions. These changes are well seen in our case. There has also been seen, in three cases, a change in the cerebellum, which does not occur in any other entity. This seems to be an alteration in the cerebellar granule neurones, though the identity of these odd cells have not, according to Richardson, been firmly established. This change did not occur in our patient.

The cause and pathogenesis of this entity remains unknown. The occurrence with conditions in which immunological hyporeactivity is a feature, first pointed out by Richardson, and has been stressed by subsequent writers. The two current theories are that this demyelination is due to an abnormal auto-immune

response, or alternatively to a secondary viral infection.

The patient I wish to describe was a musician of 49, who initially consulted his doctor because of intermittent mild upper abdominal pain. His spleen was found to be enlarged and many discrete glands were palpable in the neck, axillae and groins. Biopsy of a cervical gland was said to have revealed lymphosarcoma but no treatment was instituted as discomfort was slight and he was leading a full and active life.

A year later he was referred to Dr Pitney because of further pain, some loss of weight, and increase in the size of his spleen and lymph glands. Chest X-ray showed some enlargement of the right hilar and paratracheal glands. He was anaemic but his total and differential white cells were normal. X-ray therapy to his spleen and gland areas resulted in clinical improvement, recovery from his anaemia and reduction in the size of his spleen and virtual disappearance of the lymph glands.

He returned to work and remained well until some eight months before his death, two and a half years after the onset. Symptoms then recurred and it was noted that his spleen was enlarging and lymph glands were again becoming palpable. He was again anaemic and Dr Pitney was satisfied that haemolysis was occurring.

He was treated with blood transfusions, and nitrogen mustard. Two weeks later, because of further haemolysis, prednisalone was started with gratifying improvement. Two months later, however, there was again a relapse. He was admitted to hospital for irradiation of the spleen and shortly afterwards developed an ischio-rectal abscess which had to be saucerized.

About two weeks after this operation, he noted increasing weakness in the right upper extremity. For the next four weeks he slowly went downhill. His spleen and lymph glands were now not palpable, his haemoglobin was 12·3 gms. %, and his wound had healed, but he had developed a fever with extreme malaise and lassitude, a cough with some sputum, and increasing weakness in his right upper limb.

I saw him now for the first time. He was heavily built, somewhat moon-faced, presumably because of his steroid therapy, with some flattening of the right naso-labial fold at rest, though voluntary movement of the face was intact. He was fully orientated and co-operative, but vague about details of his illness and the mode of onset of the right upper limb weakness. It was difficult to keep him to the point, and after an initial promising start in answer to a direct question, he frequently wandered in a non sequential fashion, and would not allow interruption. He had no real insight into his illness, and asked the same questions interminably, veering inexplicably from apprehensive depression to inappropriate jocularity. He had a temperature of 103° Fahrenheit, and was sweating profusely and looked flushed and ill. There was dullness to percussion and diminished breath sounds in the right upper lobe. Neither spleen nor lymph glands were palpable. The right upper extremity was completely flaccid and markedly wasted, especially at the shoulder. He was unable to move the limb at all, except for some movement against gravity, but not against resistance, of the pectoralis, biceps, and finger flexors. The right triceps and supinator reflexes were absent, but the right biceps jerk was present. There was no abnormality of sensation and no sign of long tract disturbance. Though deep tendon reflexes in the lower limbs were very brisk, and the abdominal reflexes were absent, power and tone were normal, and the plantar reflexes were flexor. His neuropathy did not appear to be the result of compression or infiltration and I wondered about a "metabolic" neuropathy in association with lymphoma, as suggested by Hutchinson.

The patient however now volunteered for the first time that he had had a similar weakness in the right upper extremity 23 years before, while on a Norwegian cruise, and that it had recovered in a week or two without treatment. There was no corroboration of this story, but if it was true, the aetiology would be difficult to link with his lymphoma. This made me wonder about brachial neuritis of Aldren Turner type. In any event the cerebrospinal fluid findings were entirely normal and in the next few days, without any improvement in his general condition, there was undoubted improvement in power in the right upper limb. He had good abduction and adduction of the shoulder against resistance, he could hold the limb outstretched and raise it above his head for a few seconds.

FIG. 7—Frontal lobe, left, X 3·8, myelin stain, showing multifocal areas of demyelination.

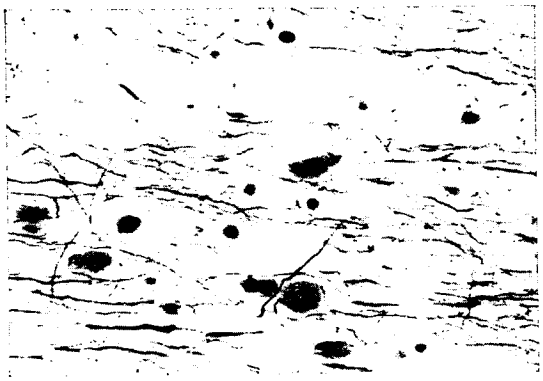

FIG. 8—Axone stain, X 500, showing relative preservation of axones in an area badly affected, as evidenced by the many and abnormal glial nuclei and macrophages.



FIG. 9—Fat stain, X 30·7, showing macrophages laden with sudanophilic products of myelin breakdown.

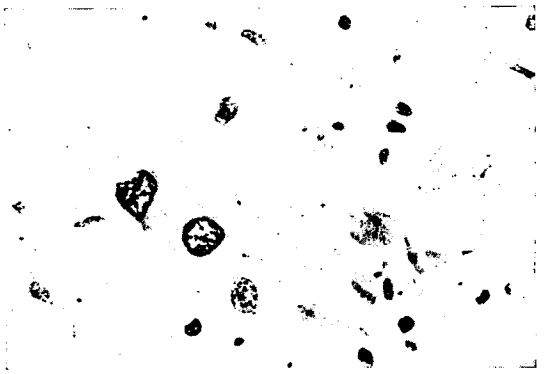

FIG. 10—H. & E. stain. X 500. Bizarre binucleated astrocyte.

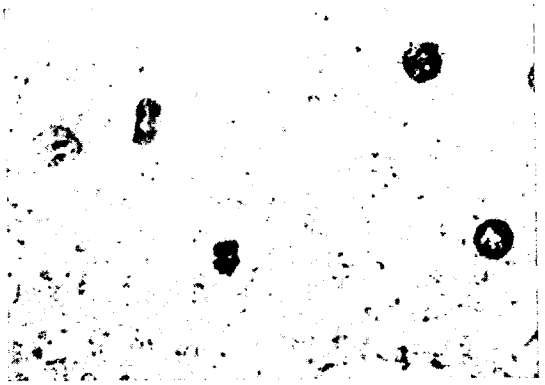

FIG. 11—H. & E. stain. X 1000. Mitotic figure with daughter nuclei.

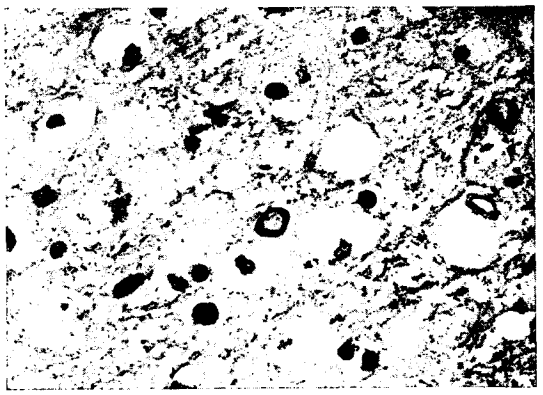

FIG. 12—H. & E. X 500. Abnormal oligodendrocytes, the central one showing an eosinophilic inclusion, and several showing dense basophilia.

FIG. 13—Median nerve, right, X 200, myelin stain, showing fibre degeneration and myelin breakdown.



FIG. 14—Right biceps muscle. X 64. H. & E. stain, demonstrating denervation atrophy.

He could also flex and extend the elbow against mild resistance. However wrist and finger movements were extremely weak. Sensation remained intact. His general condition was poor, with a high swinging fever, and no resolution of the consolidation of his right upper lobe despite antibiotics.

Three weeks after admission it was noted that he had developed marked weakness of all the muscle groups of his right lower limb, but this was of upper motor neurone type, with increase in extensor tone, augmented deep tendon reflexes and a right plantar response no longer as promptly flexor as before. His right upper limb, previously flaccid, now showed flexor spasticity of the elbow, and an increased biceps jerk. The face was unaltered, still showing the asymmetry noted on admission. Motor function was otherwise unaltered. The cranial nerves including visual acuity, fields and fundi were normal. Sensation had become difficult to test as he gave inconsistent replies. It seemed that pin prick was normally appreciated, but one could not test any other modality.

Mentally he had undergone further deterioration, but this was gradual, and though one recognized changes from week to week, one could not appreciate them from day to day. He remained alert, co-operative and orientated and his manner was reasonably appropriate. His immediate retentive memory was surprisingly good. He could recite the Babcock sentence on the third attempt, and could repeat five digits forwards, and four backwards. More remote memory was patchy, and this varied from day to day. His greatest difficulty however was with coherent and consecutive thought and judgment, and ability to calculate was poor.

It was clear that in addition to evidence of a disorder of the peripheral nervous system he had signs of cerebral disease, certainly in the left hemisphere accounting for his right pyramidal signs, but probably bilaterally to account for his dementia. In the absence of headache, neck stiffness and papilloedema, and with repeatedly normal plain X-ray and cerebrospinal findings, a negative Wasserman reaction, and a diffusely abnormal electroencephalogram (though slightly worse on the left), a diagnosis of progressive multifocal leukoencephalopathy seemed tenable.

Mental and speech testing in the ensuing days became very difficult. He was very ill, speech became hesistant and dysarthric and then clearly dysphasic. Though he could name correctly about 20 common objects, he did so only after long pauses, and spontaneous speech was frequently held up for want of a word. He did not seem to comprehend all that was said to him. He could still read a few words, but introduced frequent neologisms. A few days later he could not read at all. He had a portrait of his Siamese cat of which he had been very proud, on his bedside table, but now did not seem to recognize it, and was entirely unable to name parts of its anatomy when these were pointed out, confusing the legs with the ears, and being unable to find the tail. This was

thought to be due to visual agnosia, for though the visual fields were impossible to test at this stage, his acuity seemed unimpaired, and he could name parts of his own body correctly.

He became drowsy, his right side became weaker, he developed jaundice and numerous ecchymoses and continued to have a high swinging fever. In this stage, nearly seven weeks after I had seen him first, he died.

The general autopsy was performed by Dr John Blackwell, to whom I am indebted for the findings. Very briefly, there was a severe right upper lobe pneumonia, and only little macroscopic evidence of lymphoma, though this was found microscopically in the liver, spleen, para-aortic lymph nodes and bone marrow.

For access to the neuro-pathological material, and for the services of his technicians, I am indebted to Professor Ten Seldam. The brain and spinal cord were removed, together with portions of the anterior and posterior cervical spinal roots, the branchial plexus on both sides, and portions of the medial, ulnar and radial nerves bilaterally. No evidence of compression or infiltration was seen. Various muscle sections were taken from both upper limbs. All this material was fixed in formalin. Coronal sections of the fixed brain disclosed numerous soft pinkish grey areas in the sub-cortical white matter of the frontal lobes, especially on the left, and to a lesser extent of the other lobes, varying in size from a few millimetres to almost one centimetre. Several of these were confluent. The cerebellum, brain stem, and spinal cord appeared to be normal macroscopically.

Microscopically abnormality was confined to the cerebral hemispheres, and the peripheral nerves of the right upper extremity and the clinically affected muscles. The brain stem, cerebellum, and spinal cord were normal.

The micro-photographs demonstrate the multifocal areas of demyelination, some of which have become confluent. The axone stain shows the relative preservation of axis cylinders in a badly affected area. Fat stains show well the macrophages in the affected areas, laden with sudanophilic material. Haematoxolin and eosin stains show the bizarre astrocytes with a mitotic figure, and bi-nucleated cell. The oligodendrocyte changes with basophilia in some and eosinophilic intranuclear inclusions in others are demonstrated. The section of median nerve shows evidence of degeneration of nerve fibres with myelin breakdown. The radial and ulnar nerves showed similar changes, and changes were seen also in the cords of the brachial plexus, but the sections of the anterior and posterior cervical spinal roots were disappointing. The clinically affected muscles showed a denervation atrophy as demonstrated by the micro-photograph taken of the section of the right biceps muscle.

In summary I have described a case of progressive multifocal leukoencephalopathy presenting certain points of interest. Firstly because of Richardson's description it was possible to make the diagnosis in life. Secondly the associated peripheral neuropathy is not described in any of the other reports, and could not be shown to be due to compression or infiltration. Thirdly the demyelination developed while the patient was receiving steroid therapy. Finally the cerebro-spinal fluid was examined on one occasion for the presence of a virus, but none was found. Neither was a fungus found. It did seem to me that without cells in the cerebro-spinal fluid, these would be unlikely agents in aetiology, but they had to be excluded.

References

ASTRÖM, K. E., MANCALL, E. L., and RICHARDSON, E. P. (1958). Progressive multifocal leuko-encephalopathy: a hitherto unrecognized complication of chronic lymphatic leukaemia and Hodgkin's disease. *Brain*, 81, 93.

HUTCHINSON, E. C., LEONARD, B. J., MAUDSLEY, C., and YATES, P. O. (1958). Neurological complications of the reticulosies. *Brain*, 81, 75.

RICHARDSON, E. P. (1961). Progressive multifocal leukoencephalopathy. *New Engl. J. Med.*, 265, 815.

TURNER, J. W. A. (1944). Acute brachial radiculitis. *Brit. med. J.*, 2, 582.

THE STIFF MAN SYNDROME

J. L. ALLSOP
Sydney

IN July 1956 Moersch and Woltman[1] discussed 14 cases exhibiting "progressive fluctuating muscular rigidity and spasm" which they had previously called the "Stiff Man Syndrome". The records of these 14 cases were strangely similar. In 10 cases the onset of symptoms had been gradual, extending over months or years. In 2 cases the symptoms had developed in a matter of a few weeks and in 2 cases in a few days. The musculature of the trunk or limbs might be involved and proximal muscles tended to be more affected than distal. There was a constant base-line rigidity of muscle which might cause constant deformity of trunk or limb. The head might be hunched into the shoulder girdle and spinal deformity result. Difficulty with breathing was reported. Superimposed on this base-line rigidity there was invariable complaint of severe muscular spasms which tended to be precipitated by passive and active movement and startle. These spasms were painful, though the degree to which the patient was troubled by rigidity relative to spasm differed from patient to patient. The diagnosis of hysteria had frequently been made in these cases.

Examination revealed muscular rigidity and superimposed spasm. Voluntary movement was often reduced in rate parallel to the degree of rigidity, but there was no detectable weakness, despite the complaint of this symptom. The deep reflexes were normal or slightly increased and the plantar responses usually normal, though in 5 cases there was difficulty in interpretation. Special investigations were not helpful. The course was one of gradually increasing disability, with death in 4 cases after an average period of 9 years.

In February 1958 Richard Asher[2] reported in characteristic style the case of a "Woman with a Stiff Man Syndrome". He made this diagnosis in retrospect in the case of a woman he had seen 10 years previously. He was able to trace the patient and re-examine her before her death in June 1957, at the age of 65, in the course of a generalized muscular spasm. In this case the muscular spasms were of extreme severity, causing intense pain and leading to the fracture of the neck of the femur. Subsequently a Smith-Petersen pin was bent during one of these spasms. The physical findings were much as described in the previous paper, but constant spasm of the lower limb muscles had produced a gross talipes equino-varus. Special investigations were unrewarding. At post-mortem some minor changes were reported in the muscles suggestive of a muscular disorder, but the true pathology was considered to be uncertain. It is interesting to note that this patient had been considered hysterical for many years.

Following this, in March 1958 a further retrospective case report was furnished by O'Connor.[3] In this case also the neck of the femur had been fractured and the Smith-Petersen pin bent.

In March 1958 Price and Allott[4] reported a further case in which constant deformity of the left hand and of both feet was produced by increased muscle tone and spasm. These workers reported a rise in the serum inorganic phosphate after the ingestion of glucose. Electromyography revealed continuous muscle activity at rest. Muscle biopsy showed no abnormality.

In 1958 and 1959 I[5] was fortunate to see 2 cases considered to be suffering from this condition. The history and the physical examination in each case were as described by previous writers. The occurrence of painful muscular spasms was reaffirmed as an important symptom and sign. Difficulty with walking, associated with falling, was noted, due to muscle stiffness and spasm in the trunk and lower limbs. The rigidity of the muscles was neither of the clasp-knife nor of the cog-wheel type, but an intense plastic type of rigidity. The abdominal muscles were board-like and there was marked concavity of the lumbar spine so that when lying flat a hand could be slipped under the back. There did appear to be slight loss of power in

the affected muscles. The spasms, which caused intense distress, were brought on by passive manipulation, by voluntary movement, by cold, by emotional distress, and painful skin stimulation. Emotional precipitation was prominent in one patient who was unhappy in marriage, and needless to say, this patient had been diagnozed previously as an hysteric. The electromyogram in both cases showed continuous muscle activity without any fibrillation. Spasm was noted on voluntary contraction and on movement of the needle. The muscles were studied by muscle biopsy using intravitral staining with methylene blue, and in one case at autopsy. The findings could not be considered as conclusive. There was, however, some evidence of neural atrophy and some abnormality of the terminal aborisations of the intramuscular nerves. Dr B. Turner reported that the changes found in the terminal innervation of the fibres bore some resemblance to that described as occurring in diseases of the upper motor neurone or Parkinsonism.

After considering these cases, a fairly clear clinical picture results. Of the 18 cases reported in some detail in the literature, 11 were male and 7 female. The age of onset ranged from 28 to 73 years and averaged 43 years. The most striking feature was muscle spasm which might be extremely painful and sufficient to fracture a bone or bend a Smith-Petersen pin. When localized, the spasm resembled an ordinary cramp, but if generalized resembled a tetanic spasm. Aggravating factors were active and passive movement, emotional stress and excitement, painful stimulation of the skin, and exposure to cold. Associated with the spasms was persistent contraction of the muscles which was worse in cold weather. The changes seemed to be most pronounced in the trunk and back, in the lower rather than the upper limbs, and in the proximal rather than the distal part of the extremities. The onset was usually insidious, though occasionally rapid. Six cases ended fatally after an illness lasting from 6 to 15 years. Death may undoubtedly result from a series of generalized muscle spasms in a bed-ridden patient. Rigidity of muscle may sooner or later make it impossible for the patient to stand or sit up. He tends to fall in one piece like a wooden man. Treatment appears to be unrewarding as far as the muscle-stiffness is concerned, but spasm seems to be helped by phenobarbital, procainamide, chlorpromazine, myanesin, singly or in combination. The cause is quite unknown.

With this background I would like to report a case with many similarities to the Stiff Man Syndrome but which I believe differs in certain important respects. I do this as I believe the aetiology of patients broadly presenting in this fashion may vary.

The patient was seen by me in October 1961. She was an Italian woman of 39 whose illness began in June 1961 with soreness of the epigastrium made worse by exercise and bending. There was some nausea, vomiting and loss of weight, but a barium meal showed no abnormality. In June 1961 she also noticed giddiness, unsteadiness of gait and blurred vision, more marked in the right eye, sufficient to interfere with her reading. The visual symptoms cleared up after a week. Shortly after this she noticed stiffness of the muscles of the neck, back and right upper limb. She was seen in a general clinic where rigidity of the abdominal muscles was noted. Caloric tests were normal. Her giddiness improved but the muscular stiffness remained. She was referred to a psychiatrist who would not entertain the diagnosis of a functional disorder and referred her to the neurological clinic. On examination the reflexes were symmetrically brisk but the plantar reflexes were flexor and were so on two or three subsequent examinations. Retinal degeneration was noted in the region of the right macula. There was some diminution of power in the right upper limb and both lower limbs. There was a moderate to marked plastic type of rigidity in these limbs, but no clasp-knife phenomenon nor cogwheeling. The abdominal muscles were rigid and the muscles of the spine and the trapezei were prominent and stiff. Movements of the neck were difficult. She walked with a peculiar stiff gait with the arms abducted in a fashion rather reminiscent of a wrestler. It is to be emphasized that there was no history of muscle spasm or cramp, nor any suggestion of cramp in the examination. There was no pain other than a mild ache in the rigid muscles. At this stage it was thought possible that she might be suffering from the "Stiff Man Syndrome". She was referred to Professor Trethowan who had

seen the previous case with me. He confirmed that the patient was not suffering from a psychiatric disorder and thought it possible that this could be an early case of the condition but expressed some reservations and drew attention to the absence of cramp. It is interesting that independently the patient sought the advice of Sir Charles Blackburn who wrote a long report, describing precisely our findings and expressing the opinion that this did not appear to be any of the usual neurological conditions. I mention this in case it might be thought that the patient was being viewed through the eyes of a short-sighted enthusiast. The patient was admitted to hospital where the above observations were confirmed and it was noted that there was slowness of voluntary movement of the affected parts and some mild aching pain, but no cramps. A large number of special investigations were performed with negative results. She was seen in consultation by Dr Lance who drew attention to the early history of episodic blurred vision and vertigo and ataxia. He noted the presence of a left extensor plantar response. This finding, which had previously been absent, has remained in subsequent examinations. An electromyogram was performed with findings different from those of the two previous patients with the Stiff Man Syndrome. A few motor unit discharges were seen at rest but not the continuous activity of the previous patients. There was no tendency to spasm. The right biceps muscle which was the seat of great rigidity was infiltrated in its proximal portion with 1% procaine. The increase in muscle tone disappeared in the biceps. The biceps jerk was abolished to clinical and electromyographic testing with complete preservation of muscle power. This was interpreted as meaning that the rigidity was due to gamma efferent discharge. Biopsy using methylene blue supravital staining was performed. This showed some abnormality of the terminal aborization of the nerve endings but no intrinsic muscular disease. Some relief was obtained with artane and librium. The patient has been subsequently observed and her condition has remained approximately the same. The diagnosis in this patient is not known, but it is considered that her condition differs from previous cases of Stiff Man Syndrome, (1) in that there are no cramps, (2) in that there are other manifestations of central nervous disorder, namely, vertigo, ataxia, and the history of blurred vision and an extensor plantar response. It would appear likely that her muscular rigidity is a manifestation of extrapyramidal disease despite the presence of the extensor plantar response on one side. This was absent in the early stage of the disease as testified by independent observers and it is to be noted that the maximal muscular rigidity was in the right arm whereas the extensor plantar was on the left.

Another disorder of increased muscle tone has recently been reported by Isaacs[6] from Johannesburg. He terms this "armadillo disease". In these cases the increased muscle tone is accompanied by continuous fasciculation of the muscle. The electromyogram shows a continuous electrical activity at rest without the appearance of normal motor unit potentials but suggesting spontaneous contraction of large numbers of individual muscle fibres. These cases are stated to be helped by Dilantin.

It would therefore seem that there are cases exhibiting muscular rigidity with or without painful cramps which do not have the usually seen types of pyramidal lesion or of extrapyramidal disease. Before placing all in some such category as the Stiff Man Syndrome it behoves us to examine them carefully with an open mind and to employ all possible means of anatomical, biochemical and physiological examination to enable us to make a rational diagnosis.

References

[1] MOERSCH, F. P., and WOLTMAN, H. W. (1956). Progressive fluctuating muscular rigidity and spasm ("Stiff Man" Syndrome): Report of a case and some observations in 13 other cases. *Proc. Mayo Clin.*, **31**, 421.

[2] ASHER, R. (1958). A woman with the Stiff Man Syndrome. *Brit. med. J.*, **1**, 265.

[3] O'CONNOR, D. C. J. (1958). Stiff Man Syndrome. *Brit. med. J.*, **1**, 645.

[4] PRICE, T. M. L., and ALLOTT, E. N. (1958). The Stiff Man Syndrome. *Brit. med. J.*, **1**, 682.

[5] TRETHOWAN, W. H., ALLSOP, J. L., and TURNER, B. (1960). The "Stiff Man" Syndrome. *A.M.A. Arch. Neurol.*, **3**, 448.

[6] ISAACS, H. (1961). A syndrome of continuous muscle-fibre activity. *J. Neurol. Neurosurg. Psychiat.*, **24**, 319.

SOME ASPECTS OF DISSEMINATED SCLEROSIS IN QUEENSLAND

P. J. LANDY

Brisbane

IN the search for aetiological factors the geographical and climatic distribution of disseminated sclerosis has often been investigated.

The apparent rarity in tropical and subtropical countries is mentioned by Brain. It used to be said that its incidence in Queensland was very low and its course attenuated. Similar observations have been quoted as to its incidence in Western Australia, South Africa and Japan. The amount of sunlight to which a person is exposed in the first few years of his life has been suggested by some authors as a predisposing factor.

If clinical and geographical factors affect the disease, it could be argued that the sex incidence, the frequency of the disease, the age of onset, and the course of the disease may be affected. I have reviewed these factors in 197 cases seen by me in Queensland over the last ten years.

I. SEX INCIDENCE

The sex incidence of 107 females and 90 males shows a slight preponderance in females, and this corresponds to the usual United Kingdom figures.

II. THE FREQUENCY OF THE DISEASE IN RELATION TO CLIMATE AND GEOGRAPHIC FEATURES

In trying to relate the incidence of the disease to climatic and geographical factors two yardsticks could be used, either the place of onset of the first symptoms, or the place where the person was born.

(a) *Place of Onset*

The map (Fig. 1) shows the distribution according to the place of onset, within a fifty mile radius of the town, giving a fairly uniform distribution through the populated areas, with an incidence of 1: 14,000 above the Tropic of Capricorn and 1: 6,500 below the Tropic. This latter figure closely parallels Brain's figure of 1 per 5,000 for England and Wales.

The onset of the first symptoms occurred outside Queensland in some cases, but subsequent episodes developed in Queensland.

(b) *Place of Birth*

Thirty patients were born outside Queensland, in the British Isles, Europe and other states of Australia. This was almost 15% of the whole group and corresponded to the approximate migration over a ten year period.

When the place of birth of these cases is taken into acount it does not affect the figures above the Tropic of Capricorn, but does reduce the figures below the Tropic, showing no more than the fact that migrants tend to go to the capital cities.

(c) *Hours of Sunlight*

The daily average number of hours of sunlight over the past year for Brisbane was 7·5 hours per day, Rockhampton 8·0 hours, Cairns 8·1 hours, Longreach 9·2 hours and Melbourne 6·4 hours.

It would appear that the hours of sunlight to which children are exposed do not affect the incidence of the disease, contrary to what has been suggested by some writers, as the natural history of the cases who were born and had their first onset in McKinley (north-west Queensland), Longreach, Brisbane and Charleville followed a similar course.

III. AGE OF ONSET

Is the age of onset affected by living in tropical and subtropical areas?

The following table compares this series with the Middlesex group.

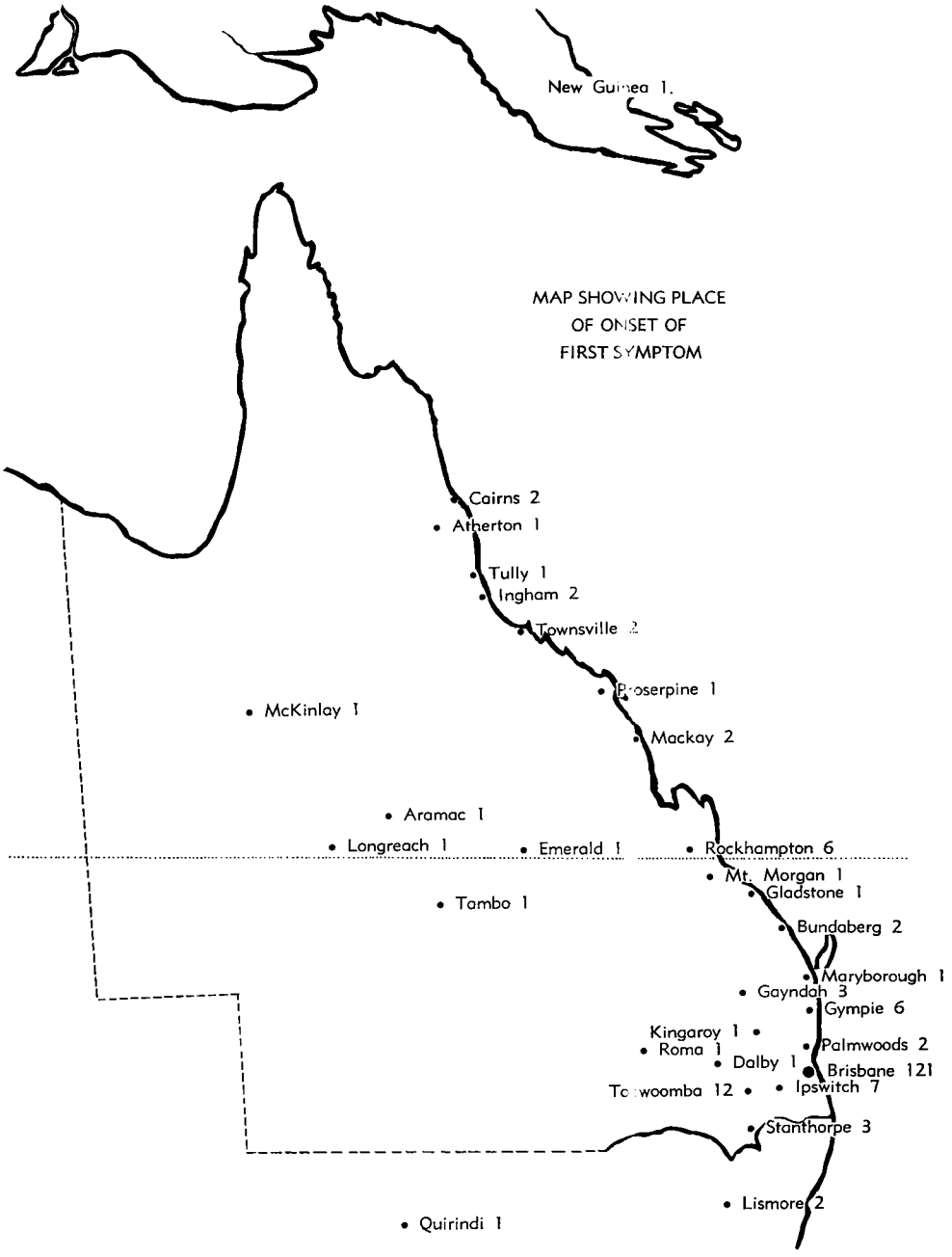
New Guinea 1.
MAP SHOWING PLACE
OF ONSET OF
FIRST SYMPTOM
Cairns 2
Atherton 1
Tully 1
Ingham 2
Townsville 2
Proserpine 1
McKinlay 1
Mackay 2
Aramac 1
Longreach 1
Emerald 1
Rockhampton 6
Mt. Morgan 1
Gladstone 1
Tambo 1
Bundaberg 2
Maryborough 1
Gayndah 3
Gympie 6
Kingaroy 1
Roma 1
Palmwoods 2
Dalby 1
Brisbane 121
Toowoomba 12
Ipswitch 7
Stanthorpe 3
Lismore 2
Quirindi 1

TABLE I

COMPARISON OF AGE OF ONSET IN TWO SERIES

Age	Present Series	Middlesex Hosp. Series
Under 20	8%	11%
20–24	12%	17%
25–29	19%	18%
30–34	23%	16%
35–39	22%	15%
40–44	9%	11%
45–49	4%	6%
Over 50	3%	3%

There is a slightly higher incidence in the 30-39 year group whereas it is slightly lower in the under 20 and over 40. Comparison with other overseas series shows even closer similarity of age of onset.

IV. COURSE OF THE DISEASE

Has climate an effect on the course of the disease and the resulting incapacity?

Table II analyses the present series in terms of incapacity, using McAlpine's classification.

Table III compares these cases with McAlpine's series over the first fifteen year period,

TABLE II

DEGREE OF INCAPACITY IN RELATION TO DURATION

Incapacity	Duration of Illness in Years				
	1–5	6–10	11–15	16–20	Over 20
Unrestricted	44	23	3	5	4
Restricted	11	16	8	4	2—23 yrs. 28 yrs.
Markedly restricted	13	14	8	5	2—24 yrs. 28 yrs.
Mobile at home	1	6	4	2	1—33 yrs.
Immobile at home	3	2	1	1	
Bedridden	2	2	2	1	
Dead	1	2	2		2
Totals	75	65	28	18	11

TABLE III

COMPARISON OF INCAPACITY IN RELATION TO CLIMATE

Degree of Incapacity	Series	Duration in Years 1–5	6–10	11–15
Unrestricted	Present series	58%	35%	10%
	McAlpine's series	60%	37%	25%
Restricted	Present series	12%	24%	28%
	McAlpine	14%	18%	18%
Markedly restricted	Present series	12%	23%	28%
	McAlpine	15%	20%	19%
Mobile at home	Present series	—	9%	14%
	McAlpine	5%	15%	15%
Immobile at home	Present series	1%	3%	3%
	McAlpine	4%	10%	12%
Bedridden	Present series	1%	3%	6%
	McAlpine	2%	8%	6%
Dead	Present series	1%	3%	7%
	McAlpine	2%	5%	5%

as beyond that the figures are so small as to make comparison difficult.

Allowing for some slight differences in personal categorization the grouping is similar, suggesting that climatic and geographical distribution has no effect on the natural history of the disease.

A review of the presenting symptoms shows a close parallel to overseas figures.

Of the seven patients who died, one was born in Turkey, one had the onset in Korea, one survived for thirty-three years and died of left ventricular failure.

Psychiatric symptoms were not prominent. Two exhibited euphoria, four were depressed, two showed hysterical features, one was in a mental hospital and one a behaviour problem.

Epilepsy occurred in six cases.

The family history was very doubtful in one case. In another the husband had suffered from disseminated sclerosis for twenty years. The wife subsequently developed subacute degeneration of the cord. In one case there was a doubtful sibling history.

There was one half-caste aboriginal in the series.

Summary

It would appear from this series that in Queensland geographical distribution, climatic conditions and the amount of sunlight do not alter the sex incidence, the age of onset nor the natural course of the disease.

There may be a lessening in the incidence of the disease in those born and living north of the Tropic of Capricorn. However, this is probably more apparent than real, for the racial effect of high Italian and Spanish migration in this area must be considered, and, secondly, the absence of neurological services in these areas could be another factor, as the incidence in south-eastern Queensland has risen to figures approximating those in England since the inception of neurology as a specialty in Brisbane.

In conclusion, it appears that climatic and geographical factors have no effect on the incidence or course of this disease.

A REVIEW OF THE FEATURES AND TREATMENT OF TEMPORAL LOBE EPILEPSY, WITH SPECIAL REFERENCE TO SURGERY

ERIC DAVIS
Sydney

THE author offers a critical review of 30 patients who have been submitted to temporal lobe ablation in the neurosurgical unit of the Royal North Shore Hospital between April 1959 and April 1962.

The majority of the patients have been drawn from the private neurological practice of the author, some from the patients attending the Neurological Clinic of the Hospital and some from the practices of colleagues. Of the author's personal series of patients who fulfilled the criteria of ftemporal lobe epilepsy, 120 patients seen in this period), 17 patients (14%) were found suitable for surgery.

ANALYSIS OF CASE MATERIAL

Sex Incidence

No significant difference was noted. Sixteen of the patients operated on were males and fourteen were females.

Age of Onset of Seizures

Twelve of the patients had their onset of seizures in the first five years, three in the second five years, four between the ages of 10 and 15, seven between the ages of 15 and 20. Two patients had their first seizure in their 20's and two between the ages of 30 and 40.

Expressed in another way, twenty-six of the patients had their first seizures in the first two decades of life and four in the next two decades.

PATHOGENESIS

On analysis of the protocols of patients submitted for surgery the folowing aetiological factors emerged:

Perinatal brain damage—such factors include dystocia, prematurity, maternal toxaemia and/or hypertension and finally anoxia . . 9

Postnatal serial convulsions 7

Postnatal infection (cortical thrombo-phlebitis or focal cerebritis from mastoid infection 1

Postnatal cranio-cerebral trauma 5

Glioma—

Oligodendroglioma (child) 1

Astrocytoma (young adult) 1

Hamartomas 4

Postnatal anoxic episode 1

Not ascertained 1

Thus, the two major divisions of temporal lobe epilepsy are apparent—the majority being associated with perinatal brain damage or serial convulsions and four associated with microscopic glial or vascular hamartomas.

DURATION OF SYMPTOMS BEFORE OPERATION

If we divide the patients into two groups, an interesting difference becomes apparent. The 26 patients whose epilepsy commenced in the first two decades might be called *Group A*. The four patients whose epilepsy started in the second two decades might be classified as *Group B*. In Group A the duration of symptoms before operation vary from 3 to 32 years with an average mean of 14 years. In Group B the intervals were 2, 7, 16 and 4 years with an average mean of 7 years. The reason for this striking difference is of course apparent. In the former group long-term anti-convulsant medication had been the therapeutic regime of choice. Two main reasons promoted further investigation and a consideration of surgery: (a) failure of drug therapy to control seizures, (b) occurrences of gross disorders of behaviour. In the second group the epilepsy was of comparatively recent onset or at an age group which demanded the elucidation of "late onset seizures".

Characteristic Seizure Patterns

Group A

(1) The majority of patients in this group presented with grand mal in infancy or childhood or with one or other of the facets of the so-called petit mal quartette epilepsy (infantile spasms, salaam seizures, inhibition epilepsy or myoclonic jerkings). It was common to find that these children later displayed the more classical psychomotor manifestations or seizures as maturity developed. This gamut was, in the author's experience, the commonest presentation in both the operated and unoperated series. Twenty out of twenty-six presented with grand mad in the pre-pubertal period, that is 77% of Group A or 66% of the total.

(2) Minor motor seizures. Twenty out of these twenty-six patients (77%) gave a clear history of tonic seizures, adversive fits or cursive seizures. Commonly these children displayed both grand mal and minor motor seizure activity.

(3) Automatisms. Twenty-two out of twenty-six of Group A developed classic psychomotor automatisms as the picture of their epilepsy unfolded.

(4) Psychical seizures. Twelve of this group developed the classic perceptual hallucinations and conceptual illusions of Penfield.

Group B

In all four patients the mode of onset was that of automatisms and psychical seizures. Two of the patients had grand mal attacks in addition.

Mental Symptoms in Temporal Lobe Epilepsy

Introduction

As generally reported in the literature the commonest type of personality change was a general slowness of mentation of varying degrees. This symptom was frequently combined with various emotional disturbances—dysphoria, irritability, emotional instability and mood changes.

Gastaut describes two major mental syndromes.

1. *The syndrome of hypo-activity* (75%). This is characterized by a general slowness of motor and intellectual processes with sluggishness of affect, emotional indifference or depression. Many of this group also display a disorder of social behaviour with explosiveness of affect and outbursts of aggressiveness.

2. *The syndrome of hyper-activity* (20 to 25%). In this group hyper-kinesia is apparent. Intellectual processes are accelerated but often characterized by lack of precision.

Pre-operative Mental and Intellectual Status

Group A

1. *Intellectual impairment.* Various degrees of retardation with a general slowness of mentation was common in this group. Of the 26 cases operated on in this group, 16 displayed varying degrees of mental retardation. All of these patients without exception had had their epilepsy since the earliest postnatal years and all in the first decade. In other words 62% of Group A displayed some degree of intellectual impairment. It must be pointed out however that none of these patients came within the imbecile or idiot groups. In fact one of the points of selection for operation was a reasonable I.Q. level. The general principle followed was that if the operation was successful, then these patients should be able to return to their previous occupation or schooling or alternatively take up a new career.

2. *Normal intelligence.* The remainder of Group A, that is 10 patients, displayed normal intelligence. In all these patients the epilepsy first declared itself in the second decade of life. This section comprised 38% of Group A.

Group B

No intellectual impairment was noted.

Behaviour Patterns

Abnormalities of behaviour are a common feature of temporal lobe epilepsy. Of the patients operated on in Group A, the following classifications were apparent:

1. *The syndrome of hypo-activity.* This is the group referred to by Gastaut, the main

features being intellectual retardation and aggressiveness. Episodic rages, temper tantrums, explosiveness of affect, violent storms of behaviour, screaming attacks were oft repeated descriptive phrases.

Seven of the patients displayed this syndrome. 27%

2. *The syndrome of Ixophrenia* (Torsten Bingley).[2] The features in this group were stickiness, moroseness, obsessional behaviour, hyperkinesia or withdrawing or schizoid characteristics.

Ten of Group A displayed this syndrome. 38%

3. *Frankly pre-psychotic.*

Two 8%

4. *Normal behaviour patterns.*

Seven 27%

Investigatory Procedures

The criteria of operability have been well established overseas and these were followed in our clinic and the usual routine methods of investigation were adopted. Thus all cases submitted to operation had a unilateral electrographic focus. Clinical examination, psychometric assessment where indicated, skiagrams of the skull, electro encephalography with Megimide activation, Pentothal and temporosphenoidal needle emplacements, air studies and cerebral angiography were all used.

In the determination of laterality of the discharging focus, most reliance was placed on the basal electro encephalogram. In one case (a left-handed patient with a right temporal focus) the intravenous Amytal technique was made use of to determine the site of the speech centre. In six patients only was there any significant contra-lateral spiking or slow wave changes. Megimide was found uniformly successful as an activating agent. The reduction of Pentothal rhythms on the side of the active focus was well displayed in a number of pre-operative electro encephalograms.

A unilateral focus was found in the left (dominant) hemisphere in 16 cases

A unilateral focus was found in the right (non-dominant) hemisphere in 14 cases

Monitoring by electro-corticography was adopted in every case.

Histopathology

All material removed at operation was submitted to histological examination. Dr Brian Turner, neuro-pathologist to the State Psychiatric services, was kind enough to examine all specimens.

With few exceptions the changes in the temporal lobe (neo-cortex) included the following—diffuse sclerosis sometimes with marked astrocytic proliferation, vascular thickening with perivascular reaction, marked glial reaction and finally in some cases myelin pallor. One patient in Group A, a youngster of 11 years, had an oligodendroglioma. One young adult of 20 years had an astrocytoma, grade one.

Uncal and hippocampal structures were submitted to examination whenever possible. Many of the mesial structures "disappeared down the sucker" but in those specimens examined typical sclerosis was found.

Pathology of the vascular hamartomas in four cases was well demonstrated by Dr Turner.

Operative Results

Apparent Cure

Post-operative period of observation:

	Group A	*Group B*
Up to 12 months	2	2
12 to 24 months	6	1
24 to 36 months	4	1

16 cases = 53% of apparent cures

Considerably Improved

This group is now fully employed or back at school. The seizures have been reduced by at least 50%.

	Group A	*Group B*
Up to 12 months	1	–
12 to 24 months	6	–
24 to 36 months	2	–

9 cases = 33% partial success

Considerably Improved but not yet Employed

1 case = 3·3%.

Apparent Failures

2 cases.

Not Traced

2 cases.

Post-operative Complications

The following could be listed:

1. A syndrome of confusion, disorientation and hypo-mania. There were five patients who displayed this as an immediate post-operative complication. Recovery took place within a matter of four to six weeks. Two patients displayed a psychosis of late onset, one of whom committed suicide and the other recovered.

2. Memory defect. Five patients displayed a transient disturbance of recall and one a more prolonged disturbance of memory which after 12 months is slowly recovering.

3. Visual disturbances. Two patients displayed transient diplopia (probably contusion to the third cranial nerve during operation). Six displayed a permanent quadrantopsia. This was always a superior quadrantopsia related to operative interference with some of the fibres of Meyer's loop.

4. Two patients displayed a transient hemiparesis.

There was no operative mortality.

It will be seen from the figures quoted that apparent cures have been obtained in 53% of patients submitted to operation. This figure corresponds closely to the results reported from overseas clinics. Whilst this is not a high percentage it clearly indicates that surgery has a place in the treatment of temporal lobe epilipsy.

Cure is taken to mean not only cessation of seizures but some improvement in the behaviour patterns. This double result has been apparent in the follow-ups of these patients. Partial success refers to the reduction in the seizure frequency and in the reductions of the level of anti-convulsant medication which has occurred *pari passu* with the lessening of the seizures. In this group disorders of behaviour have responded but little to surgery although in two children particularly, with florid and outrageous behaviour patterns, the episodes showed considerable improvement.

OBSERVATIONS ON THE PROGNOSTIC SIGNS FOLLOWING RELIEF OF SPINAL CORD COMPRESSION

ANTHONY FISHER
Perth

BEFORE the dawn of neuro-surgical enterprise, which in the spinal region he initiated, our great preceptor Gowers stated that the prognosis of spinal cord compression scarcely needed formulating. The chance of any return in power in the paralysed part was small, although not quite absent if the progress of the compression itself was slow. The chief difference was in the time that life was likely to last.

Sixty-five years later Elsberg, discussing the recovery from complete paralysis caused by tumours of the spinal cord, stated that "symptoms are relieved, the bedridden patient walks again, and the paralysed and helpless patient in many cases resumes his former life of activity".

Our own results have not always been so promising and while it is obvious that these recorded views represent both extremes, there are clearly many patients who fall into an intermediate group in which even rapid and accurate diagnosis and skilful surgery produce less than the optimal result. Current attempts to gauge the prognosis following relief of spinal cord compression in any individual instance are nullified by lack of precision in documented reviews of the subject. Stimulated by the comments of Tarlov, we began observations two years ago.

Ideally one should have begun with patients suffering complete paralysis and absolute loss of sensation but, excepting spinal cord injury, such cases have been seen rarely, and only then as a result of rapidly advancing maligant neoplasm. We decided to study therefore incomplete lesions in the hope that this would produce some useful information.

In the second Goulstonian lecture for 1848 Gull quoted an observation of Brodie that "in spinal affections when recovery takes place the restoration of insensibility usually precedes that of power of voluntary motion". In this context Brodie referred to superficial forms of sensation. We therefore wondered whether the time of recovery of the spino-thalamic tract after relief of compression could give any indication of the likelihood of full motor recovery. Accordingly post-operatively daily formal examination of the patients was made for 10 to 14 days. An immediate difficulty appeared, which is familiar to all who deal in any way with paraplegic patients. Sensory recovery does not take place invariably in a smooth fashion like the rise or fall of a stage-curtain. It is frequently patchy and even the areas of recovery may fluctuate in extent and apparently move topographically at this time. Should one take the first appearance of sensation as the indicator or wait for a full return, which experience teaches may be long-delayed or indeed never achieved? As the study progressed, it was clear that this fluctuation in sensory appreciation subsided within a variable time interval and we took this point of subsidence as the mark of sensory return. We had attempted to relate the total duration of the illness to the outcome following relief of compression. We found it difficult to define accurately the onset of the disease using sensory symptoms as the criterion, because pain, of which many patients complained, bore an inconstant spatial relationship to the final pathological process. Accordingly attention was concentrated pre-operatively on incapacitating motor symptoms. The appearance of these was frequently abrupt, and in only two instances extended beyond two months. Limb weakness was not augmented in any patient by spinal puncture despite our anxieties.

Recovery of motor power was gradual and sometimes difficult to assess, but the ability of the patient to walk, with or without an appliance such as a stick or a calliper, was taken as the final goal. Some of the problems encountered can be illustrated by the following patients:

CASE I. While lifting a heavy log a timber-hand aged 65 years noticed stabbing pain between the scapulae. With rest this improved and he returned to work in three weeks. Subsequently he noticed tingling paraesthesiae in the legs. Initially intermittent, they later appeared while lying in bed. Five weeks before he was seen the gait had become lurching in quality and increasing weakness in the legs forced him to cease work. Aching discomfort was now appearing irregularly in the interscapular region. Evacuation of the bowels had been difficult and required purgation for at least three weeks. There was a tender solid mass 4 cm. in diameter lying to the left of the midline, at the level of spinous processes of the third and fourth thoracic vertebrae. There were signs of spinal cord compression at the level of the fifth thoracic segment. Plain radiograms were not significantly abnormal. Blood Wassermann reaction was negative. There was a hydrodynamic obstruction on spinal puncture. The fluid contained 43 lymphocytes per cubic millimetre and 1·5 grams per cent of protein. There was an end-zone precipitation in the colloidal gold reaction. Screening after injection of contrast medium showed splitting of the column behind the 10th thoracic vertebra with a total block at the 6th thoracic vertebra which seemed more apparent on the right side. Upper thoracic exploration was performed on that day and the dura was seen to be invested within the limits of the exposure with tough granular tissue which was lightly adherent. Most of the posterior aspect of the tissue was removed but the theca still did not pulsate. The mass in the left para-vertebral region was excised and this was composed of interlacing bands of fibrotic tissue with a degenerating centre. Microscopy of the extra-dural tissue showed chronic inflammatory changes with large numbers of plasma cells. The mass in the soft tissues was a gumma. Two days later the Wassermann reaction in the C.S.F. was reported to be strongly positive. The post-operative course was stormy. Sensory recovery was complete in the right leg in 24 hours, and it was three weeks before the areas with normal sensibility were seen in the left flank, in the outer aspect of the left thigh and in the left popliteal fossa. Sensory recovery was eventually complete. Correspondingly motor recovery was sluggish though he was able to walk with difficulty, using leg callipers in 12 months. A full course of anti-syphilitic drugs resulted in reversal of the Wassermann reaction of the cerebrospinal fluid, disappearance of cells and the production of a paretic gold curve.

CASE II. Nine months before I saw a clerk aged 39 years she had awakened suddenly to find the right hallux numbed. This disturbance continued and one month later she experienced a sensation of heaviness in the right leg which she began dragging. In a further month gnawing pain relieved only by recumbency appeared in the centre of the back at the mid-thoracic level. Since then the right leg had become weaker, and for two weeks she had been unable to feel the passage of faeces. Examination showed a spastic monoparesis affecting the right leg, with an associated defect in the sense of passive movement in the right foot. The anal sphincter had poor voluntary power of contraction. Superficial forms of sensation were intact. Radiograms of the thoracic spine were not abnormal, though calcification in the 9th thoracic disc space was noted. The cerebrospinal fluid protein was 46 mgs. per cent and the dynamics were normal. The contrast column was persistently arrested at the 10th thoracic vertebra where the cord was deviated to the left. In the lateral projection an ovoid filling defect was seen on the anterior aspect of the contrast column at the level of block. Operation revealed a large ossified protrusion from the disc between the 9th and 10th thoracic vertebrae indenting the dura anteriorly on the right side. Following its removal, the dura did not pulsate, and on opening the membranes there was a severe degree of thickening of arachnoid and dura anteriorly and the cord was a little bruised. Post-operatively there was a flaccid paraplegia with a sensory level extending to the 10th thoracic segment. Within three days painful stimuli could be perceived in the 4th sacral segments, and after six days this recovery had extended to the second sacral segment on the right side. There was at this time also some perception of pain in the first lumbar segment on both sides. There is still, two years later, a subjective impairment of appreciation of pain in the left leg. The patient became able to walk five months post-operatively, but only while using a calliper on the right leg and with elbow crutches.

CASE III. A farmer aged 48 years had had at least three episodes of weakness of the legs and trunk during the three years prior to my initial interview. Two of these attacks were accompanied by some sensory impairment in the legs. He was treated on one occasion with arsenicals, on another with vitamins and finally with steroids. Eventually he returned to complete normality. A fourth attack had precipitated our consultation only because a serial trial of the three previous remedies had failed. Examination revealed signs of spinal cord compression in the lower thoracic region. X-rays of the thoracic spine were normal apart from a scoliosis in its upper third. There was a manometric block at lumbar puncture. The cerebrospinal fluid contained 20 degenerating red blood cells and 1·9 gm. per cent of protein. The Wassermann reaction was negative in blood and cerebrospinal fluid. Myelography showed an almost complete obstruction to flow of contrast at the eleventh thoracic vertebra with a pattern above the block indicative of an arterio-venous malformation. Exploration revealed a dense arachnoiditis at the predicted level with a vascular malformation in the cord above this. The cord was freed from constriction but there was no interference with the malformation. Post-operatively there was a recovery of sensation in five days in the trunk and left leg. In the right leg sensation was impaired from the lower third of the thigh downwards in a stocking fashion except for a patch of normal sensibility in the postero-lateral aspect of the right shank in its lower third.

The patient was able to walk well in one month. Subsequent attacks of paraplegia have occurred and he

had a minor spinal subarachnoid haemorrhage eighteen months after the operation. From these incidents he has made a good recovery, and there were no abnormal neurological signs when he was examined two months ago.

CASE IV. Twelve months before being seen, a 57 years old butcher was briefly unconscious when he was knocked from his bicycle by a truck. Thereafter he experienced lancinating pain on the inner border of the right forearm extending to the right 4th and 5th fingers with some pain also in the tips of left 4th and 5th fingers. Within four weeks he observed some difficulty in placing his feet accurately, but weakness in the legs did not appear until 10 months later when it was accompanied by precipitancy of micturition and of defaecation. Examination showed a moderate weakness of both legs, more obvious on the right side, with defective posterior column sensation on the right and a superficial sensory defect more dense on the left side as high as the first thoracic segment, but with sacral sparing. The blood Wassermann reaction was negative and full blood examination was normal. Radiograms of the cervical spine showed only a moderate spondylosis. There was an incomplete spinal block with a cerebrospinal fluid protein content of 230 mgm. per cent. Myelography revealed the anticipated lesion. Post-operatively there was a progressive descent of the sensory level and a widening of the area of sacral sparing. Sensation was normal in seven days, and the patient walked freely and normally in three weeks.

The observations in thirteen patients are summarized in the following table:

	Level of Compression	*Onset Symptoms*	*Onset Motor Symptoms*	*Sensory Return*	*Walking*
F. Le.	T5	Three months	Five weeks	1 day	12 months
M. Jo.	T9	Nine months	Eight months	3 days	5 months
C. Sm.	T6	Three years	Ten hours	5 days	1 month
C. Ro.	T5	Five months	Two weeks	1 day	2 months
G. Gi.	L2	Eight weeks	Seven weeks	5 days	3 months
J. Sta.	T5	Twelve months	Six weeks	2 days	1 month
E. Ha.	T1	Five months	Four weeks	Nil	Nil*
P. Ma.	T1	Six months	Two weeks	12 days	6 weeks
R. Sc.	T2	Ten years	Two weeks	2 days	3 weeks
J. Pa.	C3	2½ years	Ten days	(legs—3 days) (arms—3 months)	2 weeks
S. Fr.	T7	Four months	Two days		12 days
J. Ai.	L1	Three years	One month	4 days	3 weeks
J. Sc.	T1	Twelve months	Four weeks	7 days	3 weeks

* Died—one month post-operatively from disseminated carcinoma of bronchus.

It can be seen that the onset of grave motor symptoms is relatively short, but excepting one patient with metastatic carcinoma, who died one month after operation, all were able to walk, though many had some defect in performance, some from failure of recovery of the posterior columns as much as from the pyramidal lesion. The early return of spino-thalamic sensation appears to indicate a favourable outlook for motor recovery, but the time of appearance of the latter bears little relationship to the former.

The observations have confirmed that there is considerable variation in the resistance to compression of the several fibre pathways in the spinal cord. Functionally the lateral and posterior columns appear more susceptible to pressure than do the spino-thalamic tracts.

It is possible that the retention or early return of appreciation of pain may reveal the incompleteness of a compressive lesion with its accepted better prognosis. Our observations are fragmentary and unfinished and it is clearly premature to attempt to place the findings under more general laws.

I am grateful for the opportunity of working closely with Mr George Bedbrook, F.R.C.S., Director of the Paraplegic Unit in Western Australia. It is a pleasure to acknowledge the technical skill and diagnostic ability of my surgical colleague, Mr Ross Robinson, F.R.A.C.S.,

who has provided the answers to the majority of these problems.

References

ELSBERG, C. (1941). *Surgical Diseases of the Spinal Cord, Membranes, and Nerve Roots.* New York, Hoeber.

GOWERS, W. R. (1899). *A Manual of Diseases of the Nervous System.* 3rd ed. edited by Sir W. R. Gowers and James Taylor. Vol. 1. London, J. & A. Churchill.

GULL, W. W. (1894). *A Collection of the Published Writings of William Withey Gull,* Bart., M.D., F.R.S., Physician to Guys Hospital. London, New Sydenham Society.

TARLOV, I. M. (1957). *Spinal Cord Compression.* Springfield, Ill., C. C. Thomas.

ACUTE ENCEPHALOPATHY IN CHILDHOOD

R. McD. ANDERSON
Melbourne

INTRODUCTION

THE problem I wish to introduce, today, is that of acute encephalopathy in childhood. For the purposes of this discussion the term encephalopathy is used where no inflammatory cell accumulations were found in the brain, at autopsy, following a clinical course suggesting encephalitis. Some of the causes of encephalopathy are known and include lead intoxication, hepatic failure, uraemia, hypertension, acidosis, hypernatraemia and hyperthermia especially when associated with convulsions. However, in the cases under discussion the cause, in most instances, remains obscure.

MATERIAL AND FINDINGS

During the 1950-61 period, at the Royal Children's Hospital, Melbourne, there were 42 autopsies carried out on children who died following an illness suggesting encephalitis. Of these approximately half (22 cases) showed histological evidence of encephalitis whilst in the other half (20 cases) no evidence of inflammatory cell accumulation was found in the central nervous system. These latter cases have been termed encephalopathy.

ENCEPHALITIS (22 cases)

There are a few points which should be mentioned concerning the encephalitic group of 22 cases before discussing the encephalopathies.

In 12 of the encephalitic group the histology was characteristic. This group comprised 4 cases of Murray Valley Encephalitis, 3 of Encephalomyocarditis (Coxsackie), 3 of Polio-encephalitis, and one each of Herpes Simplex Encephalitis, and Cytomegalic Inclusion Disease (Salivary Gland Virus). The virus was recovered from some of these patients.

In the other ten cases the histology was not characteristic and varied in degree from slight inflammatory cell accumulations to severe diffuse encephalitis. In none of these was a virus recovered.

In the whole group with encephalitis the cerebrospinal fluid usually contained an increase of cells at the initial lumbar puncture. It is also notable that after even a short clinical illness (in one case six hours) histological inflammatory changes were well marked.

ENCEPHALOPATHY (20 cases)

Eleven of these cases occurred in the three year period 1959-61. The significance of this apparent increase in incidence is not clear and it does not seem related to any particular drug therapy used during this period.

Although it is probable that this is a heterogeneous group of cases in many there was a fairly similar clinical pattern. The ages ranged from a few months to 12 years and the sexes were equally affected. The average duration of the illness was seven days. At the onset there was fever associated with a cough followed shortly by drowsiness and vomiting. Within a few days epileptic twitching usually occurred and was associated with a deterioration of consciousness leading to coma. At this stage pupillary changes, respiratory irregularity and decerebrate spasms occurred. Death in all cases was due to respiratory failure. Late in the illness papilloedema was sometimes present. Four of the patients had a transient skin rash early in the illness, and two had diarrhoea.

In contrast to the patients with encephalitis, the cerebrospinal fluid withdrawn at initial puncture was always normal. However, lumbar puncture repeated later in the illness sometimes showed a mild rise in cells. The pressure of cerebrospinal fluid was usually recorded as normal, but was sometimes raised.

The blood white cell count was usually raised and showed a neutrophil polymorph leucocytosis. Serum electrolyte estimations, in several cases, were normal or varied only mildly from normal.

At autopsy the outstanding finding, in all cases, was a swollen heavy brain. In many a

fatty liver was present, and mild inflammatory changes were frequently noted in the respiratory tract. Death was considered to be due to cerebral swelling.

Histological examination of the brain showed dilated pericellular spaces. In some cases degenerative changes were noted in neurones. These changes appeared anoxic in type and were especially seen in those cases where artificial respiration was used in the patient after the cessation of spontaneous respiration. In view of the fatty change seen in the liver in many cases fat stain were carried out on the brain, but no evidence of fat embolism was found.

In the liver fatty change was usually well marked. The cell nuclei were normal and it was felt that fatty change was probably nutritional in origin related to vomiting and inadequate diet during the illness.

Inflammatory changes in the respiratory tract, when present, were mild.

Discussion

Acute encephalopathy in childhood presents a difficult problem. The central feature is the development of cerebral oedema.

The clinical onset of the illness with fever, cough and drowsiness suggests an infective basis. However, the absence of an inflammatory cell response is against the direct action of a micro-organism on brain tissue, and also against an allergic type reaction following infection. The action of an unknown bacterial toxin is not ruled out.

Vomiting was a prominent feature of the illness, but whether this was primary, or secondary to the development of cerebral oedema, is not known. The finding of normal or near normal serum electrolytes would suggest that the vomiting was not a primary cause of the cerebral oedema.

At some stage epilepsy occurred in most cases; however it was not usually an initial feature and was sometimes only present in the terminal stages of the illness. Hypoxia or hyperthermia associated with severe epilepsy may cause neuronal damage, but in these cases it appears that the epilepsy was a result of cerebral oedema rather than a cause of it.

Recently Lyon, Dodge and Adams have reviewed the literature on this subject and included an additional 16 cases of their own. They were unable to come to any definite conclusion as to aetiology.

Summary

In the 1950-61 period at the Royal Children's Hospital, Melbourne, there were 42 autopsies performed on children dying following a clinical illness suggesting encephalitis.

In approximately half of these cases no evidence of inflammatory cell accumulation was found in the brain. This condition has been termed acute encephalopathy. The findings and aetiology of the condition in this group of patients is discussed.

Reference

Lyon, G., Dodge, P. R., and Adams, R. D. (1961). The acute encephalopathies of obscure origin in infants and children. *Brain*, 84, 680.

DEEP SENSIBILITY

A. K. McINTYRE
Melbourne

ALTHOUGH the clinician frequently applies tests to determine the integrity of deep sensibility, its neurophysiological basis has not yet been fully determined. It appears that Charles Bell first formulated in clear terms the idea of sensory feedback from a voluntarily moving part; in 1826, according to Liddell (1960), he wrote: "Between the brain and the muscle there is a circle of nerves; one nerve conveys the influence of the brain to the muscle, another gives the sense of condition of the muscle to the brain". Perhaps partly as a result of this, the expression "muscular sense" came into use to designate the ability to detect position and movement of the bodily parts. The notion of sensory feedback from the engines of movement themselves became firmly established when Sherrington (1894) demonstrated the extensive afferent innervation of muscle, an achievement naturally followed by widespread acceptance of the view that conscious proprioception depends largely on the flow of impulses from the newly disclosed muscle receptors. However, during the past decade or so evidence has been accumulating which seriously challenges the validity of this belief. It now seems probable that muscle receptors, though intimately concerned in subconscious reflex mechanisms and the signalling of excessive or harmful stimulation to the sensorium, play little or no part in the awareness of position and movement. It seems appropriate to begin this brief review by drawing attention to the types of receptor found in skeletal muscle and its afferent fibres.

Receptors and Afferent Fibres of Skeletal Muscle

In addition to the slowly adapting muscle spindle and tendon organ stretch receptors, there are in skeletal muscles occasional Pacinian corpuscles, a variable number of smaller lamellated receptors termed paciniform corpuscles and many freely branching, unspecialized nerve terminals. Studies of single fibre discharges such as the classical work of Matthews (1933), and many more recent investigations, have shown that the only receptors in muscle specifically capable of signalling changes in length or tension are the spindles and tendon organs. Pacinian corpuscles discharge readily to very slight mechanical disturbances, but being quickly adapting, unlike spindle and tendon organ endings, they cannot signal sustained changes in length or tension. They respond very readily to vibratory stimulation. Little is known of the smaller paciniform organs, but similar receptors of joints behave much like the larger Pacinian corpuscles. As for free nerve endings, available evidence indicates that these are mostly rapid in adaptation and respond to strong mechanical pressure, especially on tendons and fascial sheaths, or to chemical stimulation, as when the muscle performs work under ischaemic conditions. Few if any would be effectively stimulated by changes of tension or length within ordinary limits, and many—probably the majority—could be classed as nociceptive.

Probably the majority of the free endings are served by fibres of small calibre, myelinated fibres of diameter less than 4μ (Group III fibres in the terminology of Lloyd, 1943), or unmyelinated "C" (Group IV) fibres (Paintal, 1960; Bessou and Laporte, 1960; Iggo, 1961). The few Pacinian corpuscles found in muscles probably have afferent fibres falling within the Group II range (4-12μ). Paciniform bodies are probably served by rather smaller fibres, some of which may belong to Group II, others to Group III. A large proportion—perhaps in some instances all—of the afferent fibres in the Group II range belong to spindle secondary endings (Hunt, 1954). The afferent fibres of largest diameter (12-22μ) in a muscle nerve (Group I fibres) supply both tendon organs and spindle primary endings.

It would appear therefore from the result of peripheral receptor studies that the only sense

organs of muscle capable of signalling postural data, i.e. the length or tension of skeletal muscles, are the spindles and tendon organs, the afferent fibres of which are of large and medium diameter and account for the Group I and much of the Group II bands in the muscle afferent fibre spectrum.

Central Destination and Actions of Impulses from Muscle Receptors

It seems reasonable to expect that impulses concerned in deep sensibility would impinge on the highest central nervous level, the cerebral cortex, by a relatively simple path; and clinical observations of patients with spinal cord lesions would lead one to suppose that the dorsal columns of the spinal cord would constitute part of this pathway. However, experiment does not support the view that impulses in the large Group I fibres from muscle stretch receptors enter such a path; indeed, the ascending branches of such primary afferent fibres from the hind limbs leave the dorsal columns in the upper lumbar and lower thoracic segments to impinge on spino-cerebellar neurones (Lloyd and McIntyre, 1950). Thus the largest stretch receptor fibres do not contribute to the dorsal column-lemniscal pathway to the cerebral cortex, but appear to be concerned instead with subconscious reflex adjustments at the spinal segmental and cerebellar levels.

The possibility remains that impulses in Group II fibres from spindle secondary stretch-receptor endings might be amongst those which ascend to the sensorium via the dorsal columns. Some Group II muscle afferent fibres extend further up the dorsal columns than the Group I fibres but usually very few reach as far as the dorsal column nuclei, most terminating instead at various levels on interneurones, spino-cerebellar and propriospinal neurones. Impulses in muscle Group II fibres undoubtedly participate in segmental spinal and cerebellar reflex mechanisms, also in the long spinal linkages between forelimbs and hindlimbs.

The question of which, if any, afferent fibres in muscle nerves project by simple pathways to the cerebral cortex can be investigated by electrically stimulating such nerves with shocks of carefully graded strength while examining the responses in receiving areas of the contralateral cerebral hemisphere. Because fibre threshold varies inversely with diameter, very weak shocks engage only the largest (Group I) fibres, and by increasing stimulus strength, the smaller fibres may be recruited to the volley. Such experiments in anaesthetized animals (Mountcastle, Covian and Harrison, 1952; McIntyre, 1953, 1962a) and in unanaesthetized animals with implanted electrodes (Pompeiano and Swett, 1962), have shown that impulses in Group I fibres fail to yield responses or affect cortical activity, whereas those in smaller fibres can do so. Volleys which include Group III fibres in most cases evoke cortical responses, whereas volleys restricted to fibres in the Group I and Group II range, i.e. those exceeding about 4-5μ in diameter, commonly do not. However, in some preparations and with some muscle nerves or combinations thereof, undoubted cortical responses can be seen to follow a stimulus chosen to engage Group II but not Group III afferent fibres. It does not seem likely, however, that in such instances the effective Group II fibres take origin in muscle spindles, because of the failure in many instances of such volleys to elicit a cortical response despite the substantial content of fibres from spindle secondary endings in all the muscle nerves employed. Furthermore, passively stretching a muscle or muscles fails to elicit cortical responses when precautions are taken to avoid unintentional stimulation of receptors outside the muscles stretched (Mountcastle, Covian and Harrison, 1952), though passive stretch elicits discharge from secondary as well as primary spindle endings. Although the possibility remains that variations in the resistance of synaptic barriers on the pathway could account for the fickleness of cortical response to Group II muscle afferent volleys, it seems more likely that the variability lies in the number of Group II fibres of extra-fusal origin in different muscle nerves. Some may contain a significant number of fibres from Pacinian or paciniform corpuscles in or on the muscle; others few or none; and in addition, it is now well recognized that some muscle nerves convey afferent fibres (mostly of Group II size) serving receptors outside the muscle, such as those of joints or other deep tissues (Skoglund, 1956; McIntyre, 1962a).

Proprioceptive Role of Deep Receptors Outside Muscles

Studies of joint receptors (e.g. Boyd and Roberts, 1953) have established the existence of two types well suited for providing information about position and movement of joints. One type is slowly adapting and has a characteristic steady-state discharge-frequency for each joint position; the other adapts rapidly, firing only during movement and thus being incapable of signalling direction of movement or a sustained joint position. Together, however, these can register very effectively the occurrence of even slight movement, and the slowly adapting type provides information as to its direction and the final joint position. Unlike the situation with muscle stretch-receptors, weak electrical stimulation of joint nerves or actual joint movements elicit readily detectable responses in the cerebral cortex (Skoglund, 1956; McIntyre, 1962b; Mountcastle and Powell, 1959). Furthermore, impulses from Pacinian corpuscles, many of which are found in the deep tissues other than muscles, evoke prominent potentials in the cerebral cortex (McIntyre, 1962b). The dorsal-column lemniscal system—the classical pathway for deep sensibility—is the route traversed by impulses of Pacinian corpuscle and joint receptor origin. It therefore now seems likely that the afferent input concerned in "muscle sense" comes little if at all from the muscles themselves, but instead from receptors of joints, ligaments and other sentient deep tissues, e.g. the region of the crural interosseous membrane, and the tissues surrounding the digital flexor tendons which abound in Pacinian corpuscles (Gray and Matthews, 1951; Hunt, 1961). In view of their unique sensitivity to vibration, these corpuscles are almost certainly the principal receptors underlying vibration-sense.

Evidence obtained in human subjects may also be cited. Provins (1958) reported gross impairment of the threshold for passive movement of the index finger at the metacarpophalangeal joint as a result of interrupting the afferent nerve supply to this joint (and to the rest of the digit) by local anaesthesia of the digital nerves, despite the unimpeded operation of stretch receptors in the forearm muscles which flex and extend this digit. Furthermore, Brindley and Merton (1960) have demonstrated absence of position-sense in the eye, although massive discharge of the many muscle spindles known to be present in human extrinsic ocular muscles must have taken place during the eyeball deviations employed in these experiments. However, in the case of the eye there is evidence for some non-visual awareness of actively attained eye position (Sherrington, 1918), and Brindley and Merton consider that this must depend, not on sensory feedback, as Sherrington believed, but upon judgment of the effort of will involved in moving the eyes, as postulated by Helmholtz nearly 100 years ago. In like fashion, appreciation of active movement of the limbs and other skeletal structures may also involve an element of "felt will" in addition to the undoubted feedback to conscious levels of afferent impulses. These impulses arise from a variety of receptors, but not as previously thought from stretch-receptors of muscle which appear to be concerned solely with unconscious reflex mechanisms.

References

BESSOU, P., and LAPORTE, Y. (1960). Activation des fibres afférentes myelinisées de petit calibre, d'origine musculaire (fibres du Groupe III). *C.R. Soc. Biol., Paris*, **154**, 1093-1096.

BOYD, I. A., and ROBERTS, T. D. M. (1953). Proprioceptive discharges from stretch-receptors in knee-joint of cat. *J. Physiol.*, **122**, 38-58.

BRINDLEY, G. S., and MERTON, P. A. (1960). The absence of position sense in the human eye. *J. Physiol.*, **153**, 127-130.

GRAY, J. A. B., and MATTHEWS, P. B. C. (1951). Response of Pacinian corpuscles in the cat's toe. *J. Physiol.*, **113**, 475-482.

HUNT, C. C. (1954). Relation of function to diameter in afferent fibres of muscle nerves. *J. gen. Physiol.*, **38**, 117-131.

HUNT, C. C. (1961). On the nature of vibration receptors in the hind limb of the cat. *J. Physiol.*, **155**, 175-186.

IGGO, A. (1961). Non-myelinated afferent fibres from mammalian skeletal muscle. *J. Physiol.*, **155**, 52-53P.

LIDDELL, E. G. T. (1960). *The discovery of reflexes.* Oxford, Clarendon Press.

LLOYD, D. P. C. (1943). Neuron patterns controlling transmission of ipsilateral hindlimb reflexes in cat. *J. Neurophysiol.*, **6**, 293-315.

LLOYD, D. P. C., and MCINTYRE, A. K. (1950). Dorsal column conduction of Group I muscle afferent impulses and their relay through Clarke's column. *J. Neurophysiol.*, **13**, 39-54.

MCINTYRE, A. K. (1953). Cortical projection of afferent impulses in muscle nerves. *Proc. Univ. Otago med. Sch.*, **31**, 5-6.

McINTYRE, A. K. (1962a). Central projection of impulses from receptors activated by muscle stretch. In Muscle receptors, ed. D. Barker, Hong Kong, Hong Kong University Press.

McINTYRE, A. K. (1962b). Cortical projection of impulses in the interosseous nerve of the cat's hind-limb. *J. Physiol.*, **163**, 46-60.

MATTHEWS, B. H. C. (1933). Nerve endings in mammalian muscle. *J. Physiol.*, **78**, 1-33.

MOUNTCASTLE, V. B., COVIAN, M. R., and HARRISON, C. R. (1952). The central representation of some forms of deep sensibility. *Res. Publ. Ass. nerv. ment. Dis.*, **30**, 339-370.

MOUNTCASTLE, V. B., and POWELL, T. P. S. (1959). Central nervous mechanisms subserving position sense and kinesthesis. *John Hopk. Hosp. Bull.*, **105**, 173-200.

PAINTAL, A. S. (1960). Functional analysis of Group III afferent fibres of mammalian muscles. *J. Physiol.*, **152**, 150-170.

POMPEIANO, O., and SWETT, J. E. (1962). Identification of cutaneous and muscular afferent fibres producing EEG synchronization in normal cats. *Arch. ital. Biol.*, **100**, 343-380.

PROVINS, K. A. (1958). The effect of peripheral nerve block on the appreciation and execution of finger movements. *J. Physiol.*, **143**, 55-67.

SHERRINGTON, C. S. (1894). On the anatomical constitution of nerves to skeletal muscles; with remarks on recurrent fibres in the ventral spinal nerve roots. *J. Physiol.*, **17**, 211-258.

SHERRINGTON, C. S. (1918). Observations on the sensual rôle of the proprioceptive nerve-supply of the extrinsic ocular muscles. *Brain*, **41**, 332-343.

SKOGLUND, S. (1956). Anatomical and physiological studies of knee joint innervation in the cat. *Acta physiol. scand.*, **36**, suppl. 124.

CYTOGENETIC STUDIES IN MENTAL RETARDATION

BRIAN TURNER
Sydney

MANY advances in medicine are preceded by the introduction of new technical methods and their subsequent application to clinical problems. So it has been with our knowledge of human chromosomes. Whilst a great deal is known about chomosome structure and behaviour in plants and some animals, it is only very recently that details about human chromosomes have been revealed.

Abnormalities of human chromosomes have been described which involve alterations in chromosome number, as in mongolism or the Turner syndrome, or alterations in chromosome structure as in chronic myeloid leukaemia.

In this paper I wish to present briefly two cases which have been studied at North Ryde. These cases have an unusual abnormality of chromosome structure which, by affecting chromosome behaviour, is believed to be of significance in the pathogenesis of physical and mental retardation.

The first patient is a boy, 12 years of age, of short stature and gross mental retardation. He has several congenital abnormalities including an atrial septal defect and hypospadias. Further details of the case will be published elsewhere (Turner *et al.*, 1962).

Chromosome analysis on peripheral blood leucocytes, bone marrow cells and cells derived from skin cultures showed that the peripheral blood leucocytes and skin cells contained either 45 or 46 chromosomes. The marrow cells contained only 46 chromosomes, no 45 chromosome cells being identified. All the cells with 46 chromosomes contained a characteristic ring chromosome, which on analysis appeared to be derived from one of the 6-12 group chromosomes.

Studies of ring chromosomes in other species, e.g. Maize (McClintock, 1938) have shown that separation of the ring chromatids in mitosis is liable to be hampered by entanglement of the rings. This difficulty in separation results in a bridge of chromatin being stretched between the daughter nuclei during the anaphase stage of the mitotic cycle. The entangled ring chromatids are in this way sometimes excluded from the daughter nuclei as they form a nuclear membrane. The resultant chromosome fragment forms itself into a micronucleus and comes to lie in the cytoplasm of one of the daughter nuclei. Both these daughter nuclei will then, of course, be lacking the ring chromosome.

All of these changes have been demonstrated in the present case. The formation of anaphase bridges and micronuclei can be found regularly in chromosome preparations of uncolchicined cell cultures. Micronuclei were also identified in bone marrow and in 0·3% of the mononuclear elements in peripheral blood smears. Whilst cells with 45 chromosomes in which the ring chromosome was absent formed some 10% of the cells of cultured peripheral blood leucocytes and skin, they were not identified in bone marrow material. Before a cell with 45 chromosomes can be identified it must have lost its ring chromosome in a preceding division and have survived this loss and proceeded into a further division cycle. The absence of such cells from the bone marrow preparations, which represent *in vivo* divisions, is believed to indicate that these cells in which the ring chromosome has been eliminated are lethal forms, in that they are incapable of proceeding into division.

The second case which I wish to present briefly is at present under study at North Ryde and full details are not as yet available, but will be published in full elsewhere.

The patient, a woman, aged 30 years, is of short stature with moderate mental retardation. She had been described in the past as a high-grade mongol, but on detailed examination presents few of the classical stigmata of mongolism.

Chromosome analysis of peripheral blood leucocytes shows that the majority of cells contain 46 chromosomes while some 5% have 45 chromosomes. Of the cells with 46 chromo-

somes some 50% contain a characteristic ring chromosome which on analysis appears to be derived from a member of the 13-15 group of large acrocentric chromosomes. The other cells with 46 chromosomes show a normal female pattern. Bone marrow examination shows the ring chromosome to be present in the *in vivo* mitoses.

Similarly to the first case, anaphase bridges and micronuclei can be identified, though in lower frequency as the ring chromosome is present in fewer cells.

The concept which I wish to develop from these two cases is that a chromosome anomaly could lead to developmental abnormality by a "mechanical" interference with cell division. In the first case we can see that in some 10% of cell divisions an abnormal mitosis leads to daughter cells in which a chromosome is lacking, and these aneuploid cells are incapable of further division *in vivo*. The evidence for this lethal cell line developing in the second case is, as yet, incomplete, but is highly suggestive.

The effect of this reduction in the number of viable cells produced, would be dispersed throughout the developing zygote but would be expected to be most noticeable in those organs where cell division ceases at an early age. In this respect the developing central nervous system would seem particularly vulnerable as cell division ceases within the first year of life. If we consider only the final division of all developing nerve cells, we would have a 10% formation of non-viable cell forms. The variability of the clinical features in these cases would appear to be explicable by the fact that the ring chromosome is present in only 50% of the cells of the second case, the remaining cells having a normal female karyotype.

Further studies are in progress in an attempt to identify further cases. It is probable that in the majority of instances where a ring chromosome, or other chromosome anomaly, arises in a zygote, the effects are lethal and only a small proportion of such cases are likely to develop to, and survive into, an extra-uterine existence.

References

McCLINTOCK, B. (1957). In *Cytology and Cytogenetics*, by C. P. Swanson. Prentice-Hall, Englewood Cliffs, New Jersey.

TURNER, B., JENNINGS, A. N., DEN DULK, G. M., and STAPLETON, T. (1962). A self-perpetuating ring chromosome. *Med. J. Aust.*, **2**, 56.

PSYCHOTOMIMETICS—A NEUROPHARMACOLOGICAL STUDY

DAVID R. CURTIS
Canberra

OF recent years there has been considerable interest in a group of chemical compounds which are classified as psychotomimetics, since their administration produces alterations in human behaviour, experience and perception. It was hoped that a study of the mode of action of these agents would lead to an understanding of the causes of the psychoses, and in the establishment of effective therapeutic agents. However, a close examination of the effects produced by most psychotomimetics shows that the resemblance to any of the psychoses is merely superficial, and the use of these agents in investigating the cause and treatment of mental illness has been rather disappointing. Nevertheless, these compounds are still of considerable interest, because it is probable that they interfere with or mimic the action of chemical synaptic transmitters which act upon neurones, and about which we know so little.

Several current investigations in this department have a bearing on the action of some of the psychotomimetics. Single neurones have been studied and the substances have been administered locally into the immediate extraneuronal environment of the cells. In most cases, in order to obtain measurable effects, drug concentrations have been used which probably exceed those that give rise to alterations of mental function. However, the effects that are observed—the firing of neurones, the potentiation or the blocking of their synaptic excitation or inhibition—are but relatively crude alterations in neuronal behaviour. It is probable that effects of the same type, but of lower intensity, which are produced by lower concentrations of the psychotomimetics, may be adequate to disturb the normal functioning of the complex systems of neurones, which are responsible for the maintenance of mental activity.

Our interest in 5-hydroxytryptamine (5-HT or serotonin) arose from studies which showed that lysergic acid diethylamide (LSD-25), a powerful psychotomimetic, depressed synaptic transmission in the lateral geniculate nucleus of the cat. The mode of action of this, and of several structurally related depressants, was not investigated, but it was suggested that these agents were interfering with the postsynaptic action of the excitatory transmitter which is released by the optic nerve terminals. This observation, which was made at both Bethesda and Sydney, was of some importance since the chemical structure of a compound which hinders the access of a transmitter to receptor sites may give clues to the nature of the transmitter itself. The known antagonism of LSD-25 towards the action of 5-HT upon smooth muscle suggested that the excitatory transmitter of lateral geniculate sypnapses might be related to 5-HT.

LSD-25 is an effective depressant of lateral geniculate neurones when it is administered systemically. Similar effects are obtained using tryptamine, dimethyltryptamine, bufotenine, psilocybin and ergometrine. However, many structurally related compounds are without effect and, in particular, 5-HT itself is virtually without action when administered intra-arterially to this region of the nervous system. Since 5-HT and many related compounds fail to pass across the blood-brain barrier, the detailed pharmacology of geniculate synaptic transmission could only be examined by the use of techniques which permitted the administration of chemical substances directly into the extraneuronal space.

In the electrophoretic method of drug administration, dissolved agents are ejected as ions from micropipettes by means of an electrical current. A current in the reverse direction can be used to control the diffusional efflux of the substances, and the drug administration can be combined with the recording of extra- or intra-cellular responses from single nerve cells. The pharmacology of synaptic transmission in the lateral geniculate nucleus of the cat was

investigated by means of five-barrel electrodes, a method which has been developed in Canberra. The composite electrode consists of 5 tubes fused together, the central one is used as an extracellular recording electrode and the four outer barrels contain different drugs in solution. The overall diameter of the tips of these electrodes range between 4 and 10μ. Three different methods were available for exciting lateral geniculate neurones, and a study of the effect of particular compound upon these various types of spike potential permitted an analysis to be made of its possible site of action. In the first place neurones could be excited synaptically, either by electrical stimulation of the optic nerve or by light stimulation of the intact eye. Secondly, cells could be fired antidromically by stimulating the axons in the optic radiation beneath the ipsilateral visual cortex. Finally, geniculate neurones were excited chemically by means of the local electrophoretic administration of L-glutamic acid from one of the barrels of the electrode. This excitation by an acidic amino acid can be considered a "non-specific" excitation, and is apparently unrelated to excitatory transmitter action. Consequently the use of this, and other closely structurally related acidic amino acids, is of considerable assistance in such neuropharmacological investigations, since the frequency of firing evoked by the administration of the amino acid gives an indication of the excitability of the neurone.

When administered electrophoretically near lateral geniculate neurones 5-HT has no action upon antidromic spike potentials and fails to influence the frequency of firing of individual neurones which is evoked by L-glutamic acid. Nevertheless, spike potentials produced by synaptic action are suppressed and recover rapidly when the administration of 5-HT is terminated. The failure of 5-HT to affect the antidromic spikes, and the chemical excitability of these neurones, suggests that the compound is not acting as an inhibitory transmitter, and has no depressant action upon the postsynaptic membrane, as does gamma amino-*n*-butyric acid. The suppression of excitatory synaptic action is therefore related solely to the process of synaptic excitation and it is clear that 5-HT either prevents the release of the excitatory transmitter from optic nerve terminals or prevents this transmitter from interacting with postsynaptic receptor sites.

This finding is of fundamental importance because, apart from the cholinoceptive synapses upon the spinal Renshaw cells, this is the only central synapse for which a specific chemical depressant is known. On the assumption that the optic nerve transmitter might be related to 5-HT, many tryptamine derivatives were applied to geniculate neurones. Only substances closely related to 5-HT were active, and all of these had a depressant action which was identical with that of 5-HT. Similarly, compounds that are antagonistic to the action of 5-HT upon isolated tissue preparations, such as lysergic acid derivatives, psilocin and psilocybin, were also found to be depressants of the synaptic excitation of lateral geniculate neurones by optic nerve volleys. The investigation has so far failed to find a chemical substance which might be considered an excitatory transmitter of these neurones, but a considerable amount of information has been obtained concerning the possible structure of the receptor site with which 5-HT and 5-HT-like substances interact. It has been proposed that the psychotomimetic property of compounds such as LSD-25, ergometrine, mescaline, bufotenine and psilocybin might be related to an action of these agents which interferes with synaptic transmission at central synapses which have transmitters similar to that released by optic nerve nerminals.

For some time acetylcholine has been considered a possibly important transmitter substance within the mammalian central nervous system. This has been based upon the distribution of choline acetylase, the enzyme responsible for the manufacture of acetylcholine, of acetylcholine esterase, the enzyme associated with its destruction, and of acetylcholine itself. The few neuropharmacological experiments that have been performed satisfactorily, which apparently demonstrate an action of this choline ester upon nerve cells after systemic administration, can be otherwise interpreted. It is extremely doubtful, apart from the spinal Renshaw cells, that a direct action of acetylcholine upon central neurones has been shown. Acetylcholine has difficulty in passing through the blood-brain barrier, and is a powerful activator of many peripheral sensory receptors. Consequently

many of its 'central' actions may have arisen from nerve impulses reaching neurones indirectly from these peripheral sites.

There is no doubt that Renshaw cells are cholinoceptive—that is, that they have receptors for acetylcholine which is released from motor axon collaterals. Using the electrophoretic technique for applying drugs near these cells, the pharmacology of these synapses has been shown to be practically identical with that of autonomic ganglia. Thus Renshaw cells are excited by acetylcholine and related choline esters, by tetramethylammonium and by nicotine. The synaptic and acetylcholine excitations are both facilitated by anticholinesterases—such as eserine, prostigmine and tensilon, whilst both forms of excitation are depressed by tetraethylammonium, curare and dihydro-β-erythroidine.

Naturally, this type of investigation has been extended to other neurones, and until recently, with negative results. Thus spinal interneurones and spinal motoneurones are not affected by acetylcholine. However, acetylcholine has an excitatory action upon lateral geniculate neurones which is very weak, and an excitatory action upon neurones of the ventro-basal complex of the thalamus which is comparatively strong. Usually acetylcholine is inactive when administered electrophoretically near quiescent lateral geniculate neurones, but the weak excitation is readily demonstrated as a facilitation of synaptically evoked responses. In addition, the choline ester facilitates the firing which is evoked by an excitant amino acid. This excitation is not prevented by the simultaneous administration of 5-HT and this has been considered as reasonable evidence that acetylcholine is not the transmitter which is released by optic nerve volleys. Nevertheless, it is clear that geniculate neurones have receptors with which acetylcholine molecules can interact, and it is assumed that these receptors are located at non-optic synapses upon the neurones. There is physiological and anatomical evidence that such synapses exist.

Acetylcholine has a powerful excitatory action upon neurones in the ventro-basal complex of the thalamus that are activated synaptically by volleys initiated in cutaneous peripheral nerves. The potency of this agent is similar to its effect upon Renshaw cells, but there are certain differences between the pharmacological responses of these neurones. In particular, nicotine is a weak excitant of thalamic neurones but is very potent when ejected near Renshaw cells. An analysis of the results obtained in the thalamus indicates that the excitation evoked by acetylcholine is of the "muscarinic" rather than of the "nicotinic" type, but so far the use of cholinergic blocking agents has failed to affect the synaptic excitation of the neurones. This is relative to the subject of psychotomimetics, since recently a group of such compounds has been introduced which are reputed to be anticholinergics—that is, to block a central action of acetylcholine or of an acetylcholine-like transmitter. These compounds, the 3-piperidyl benzilates, bear some similarity to atropine, and when applied to Renshaw cells depress the responses evoked by acetylcholine. However, this blocking action does not correlate closely with their ability to produce mental disturbances and, in addition, they have a local anaesthetic-like action which depresses the responses of nerve cells, irrespective of the transmitters involved.

An attempt has been made in this brief review to describe some of the central effects of some of the substances classified as psychotomimetics. Although the study of the action of these agents upon the intact animal is not without interest, studies upon single neurones are necessary in order to determine their mode of action, and to make full use of the substances in analyzing the nature of transmitter substances.

DYSTONIC SEIZURES : STRIATAL OR EXTRAPYRAMIDAL EPILEPSY

JAMES W. LANCE
Sydney

THE term "tonic seizure" is most commonly applied to a transient posture of decerebrate rigidity caused by any lesion which produces a functional transection of the midbrain (Kinnier Wilson, 1920). However, there are other forms of tonic spasms in which consciousness is retained and in which attitudes are adopted resembling those of dystonia. These attacks are considered in this paper as "dystonic seizures", a descriptive term which does not necessarily imply origin in the basal ganglia or an epileptic mechanism. Such attacks were described as "extrapyramidal epilepsy" by Sterling (1924), "striatal epilepsy" by Wimmer (1925) and "subcortical epilepsy" by Spiller (1927). They have been reported in association with encephalitis lethargica, progressive hemiplegia, hepatolenticular degeneration and congenital choreoathetosis (Wilson, 1930) and multiple sclerosis (Matthews, 1958; Joynt and Green, 1962). The posture assumed is commonly that of flexion of the upper limbs, and plantar-flexion and inversion of the foot, frequently resembling the central manifestations of hypocalcaemic tetany (Simpson, 1952).

Eight patients are presented here to demonstrate clinical variations of this unusual condition.

CASE REPORTS

DYSTONIC SEIZURES ASSOCIATED WITH OVERT NEUROLOGICAL DISEASE

(a) *Choreoathetosis*

A young woman aged 19 has had right-sided choreoathetosis since the age of 12 months. Attacks of painful right-sided tonic spasm began when she was 12 years old. They last from 10-30 seconds and may recur as often as six times a day. The right side of the face is pulled up, the right elbow, wrist and digits are flexed, and the right leg feels stiff.

(b) *Multiple Sclerosis*

A trained nurse aged 47 had suffered an attack of right-sided facial paraesthesiae 15 years ago, two episodes of diplopia 12 and 10 years ago, and a right retrobulbar neuritis 2 years ago. Each of these illnesses lasted about 3 weeks. She recently had three tonic seizures, lasting from 2-5 minutes, in the space of 2 weeks. The attacks produced a painful spasm in flexion of the left arm and leg. Her left leg has felt "unreal" to her since the seizures.

DYSTONIC SEIZURES WITHOUT OTHER INDICATIONS OF NEUROLOGICAL DISEASE

(a) *Sporadic*

A medical student aged 21 has been prone to attacks of left-sided tonic spasm since the age of 13. The attacks begin with an epigastric sensation, then his tongue, jaw and face become rigid and the left arm and leg partly flex. The attacks last less than a minute and are not painful. The frequency has varied from one in 4 weeks to six a day.

(b) *Familial*

The family tree is illustrated in Fig. 15. The attacks began at the age of 22 in the senior member (II.2), now aged 68, and at the age of 2 in his son (III.4) who is now 41. The other member of the second generation (III.5) died at the age of 37 of ulcerative colitis and was known to have had tonic seizures for the last 8 years of his life. In the 3rd generation, attacks started at the ages of 2 (IV.2), 2 (IV.4) and 3 (IV.5). The present ages of these children are 11, 8 and 14.

The seizures are of similar pattern in each member of the family. They develop slowly over 5-10 minutes,

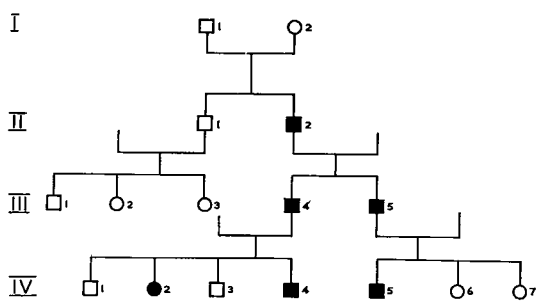

FIG. 15—Familial incidence of dystonic seizures. (Males □, females ○, affected individuals, black.)

and may last as long as an hour. The limbs, on one or both sides of the body flex, and the face, jaws and tongue are rigid. Speaking and swallowing become impossible in a severe attack, but eye movements are not affected and the mind remains clear.

Physical Signs

The first patient had signs of right-sided choreoathetosis with shortening of the limbs on that side of the body. The second patient had diplopia at the time of examination but no other indication of multiple sclerosis was present. In the remaining patients, the only physical sign noted was a minor asymmetry of the forearms in 4 of the 6, the left being shorter than the right.

Investigations

The electroencephalographic record showed non-specific abnormalities in 5 of the 8 patients. Unfortunately the opportunity to make a recording during a tonic spasm did not arise, but other authors have reported that the record does not change significantly (Joynt and Green, 1962; Biagio and Spaccarelli, 1959).

Arteriography and pneumoencephalography were carried out on 2 patients. In one of these (IV.5 of the familial cases) a small filling defect was demonstrated in the roof of the left lateral ventricle. The significance of this cannot be assessed as the other members of the affected family refused similar investigation.

Serum calcium was within normal limits in 4 patients in whom it was estimated.

Discussion

The rapidity of onset and resolution of the attacks in the first 3 patients suggests an epileptic mechanism, while the slower pace of the familial seizures resembles more the phenomena of migraine. Cranial nerve functions were involved in 7 of the 8 cases. All progressed to a state of akinetic mutism in the familial cases. Taking this in conjunction with the posture of the attacks, which is typical of basal gangia dysfunction (Denny-Brown, 1960), it seems likely that the site of the disturbance is in the basal ganglia or its afferent connexions from the cerebral cortex.

Lesions of the supplementary motor cortex are known to produce tonic seizures which bear some resemblance to those described here (Ajmone-Marsan and Ralston, 1957; Kennedy, 1959). It is probable that abnormal thalamocortical discharge plays some part in the seizure pattern as 4 of the 8 patients commented on abnormal sensations at the start of the seizures, and in two patients the seizures were extremely painful, although the degree of muscular spasm was no greater than that of other patients who did not complain of pain.

Summary

The case histories of 8 patients suffering from forms of tonic seizure are presented in two groups, depending on the presence or absence of overt disease of the nervous system. Five of the second group are members of a family in which the disorder is apparently transmitted by a dominant gene.

References

Ajmone-Marsan, C., and Ralston, B. L. (1957). *The Epileptic Seizure.* Springfield, Ill.

Denny-Brown, D. (1960). Diseases of the basal ganglia: their relation to disorders of movement. *Lancet*, **2**, 1099.

Di Biagio, F., and Spaccarelli, G. (1959). L'epilessia tonica, Policlinico. *Sez. prat.*, **66**, 830.

Joynt, R. J., and Green, D. (1962). Tonic seizures as a manifestation of multiple sclerosis. *Arch. Neurol. (Chic.)*, **6**, 293.

Kennedy, W. A. (1959). Clinical and electroencephalographic aspects of epileptogenic lesions of the medial surface and superior border of the cerebral hemisphere. *Brain*, **82**, 147.

Matthews, W. B. (1958). Tonic seizures in disseminated sclerosis. *Brain*, **81**, 193.

Simpson, J. A. (1952). The neurological manifestations of idiopathic hypoparathyroidism. *Brain*, **75**, 76.

Spiller, W. G. (1927). Subcortical epilepsy. *Brain*, **50**, 171.

Sterling, W. (1924). Le type spasmodique tétanoïde et tétaniforme de l'encéphalite épidémique; remarques sur l'épilepsie "extra-pyramidale". *Rev. neurol.*, **31**, 484.

Wilson, S. A. K. (1920). On decerebrate rigidity in man and the occurrence of tonic fits. *Brain*, **43**, 220.

Wilson, S. A. K. (1930). The Morison lectures on nervous semeiology, with special reference to epilepsy. *Brit. med. J.*, **2**, 90.

Wimmer, A. (1925). Études sur les syndromes extrapyramidaux; spasme de torsion infantile débutant par crises d'hémispasmes toniques (Epilepsie striée). *Rev. neurol.*, **32**, 281.

THE FALLING ATTACKS OF MYOCLONUS

JAMES W. LANCE
Sydney

THERE has been some doubt about the nature of Myoclonic falling attacks, as to whether they are true akinetic attacks or simply the result of an intense muscular jerk disturbing balance. Gastaut (1954) considered that "the diagnosis of seizures as astatic or akinetic is often a misinterpretation of myoclonic epilepsy". In a review of myoclonus Symonds (1954) stated: "From my own observation I am doubtful whether the falling attacks should be considered as a separate form of attack, the fall being probably due to a myoclonic seizure so brief that it is difficult to watch, and so extensive that the patient is thrown to the ground."

The opportunity to investigate the nature of falling attacks was presented by four patients who suffered from intractable myoclonus following hypoxia associated with anaesthesia, two caused by cardiac arrest and two by airway obstruction in the recovery period. The myoclonus was generalized, symmetrical and rhythmic soon after the episodes of hypoxia but, after some days, became restricted in site, affecting chiefly the limb or limbs being stimulated or moved. The patients all had symptoms of cerebellar disturbance, including slurred speech and ataxia of limbs and gait. Superimposed upon this basic movement disorder were myoclonic jerks, precipitated by attempted movement of the limbs, particularly when precision or coordination was required. Two of the patients were able to walk slowly on a flat surface, but, if they were startled or knocked one foot against a chair, a myoclonic jerk was initiated followed by a lapse of posture and a fall to the ground. Two of the patients were unable to walk without support, as any attempt to move the limbs from the standing position produced a jerk or jerks and the patient fell.

These patients were studied by recording simultaneously the electroencephalograms and multiple surface-lead electromyograms with the patients at rest, then moving one or more limbs and finally on attempting to walk.

RESULTS

1. The electroencephalograms showed abnormalities in three of the four patients. The abnormal pattern was that of a spike or multiple spikes followed by a dihasic slow wave. Normal cerebral rhythms were suppressed for the duration of the slow wave. The spikes arose from the midline central electrode in two patients whose myoclonus affected the lower limbs predominantly, and from the paracentral electrode in one patient whose upper limbs were chiefly involved. In the latter case, the spikes were of higher amplitude on the side opposite the jerking limb.

2. The electromyograms showed that myoclonic jerks were accompanied by one or more high voltage action potentials, which were followed by cessation of the normal interference pattern for a period of up to 340 msec. During this "silent period" the limb was observed to drop if it was being held against gravity, and the patient fell if in the standing position.

3. Correlation of electroencephalograms and electromyograms: Most, but not all, of the abnormal cerebral complexes were followed by a myoclonic jerk. When multiple cortical spikes were recorded, they usually increased in amplitude progressively and myoclonic discharges in muscle augmented in a similar fashion, with a one to one relationship. The latency from the initial positive deflection of the cortical spike to the muscle spike varied from 7 msec. for the occipital muscles to 32 msec. for the quadriceps. The period of muscular silence after a myoclonic jerk was of the same duration as the diphasic slow wave which appeared after the cerebral spikes.

4. Investigation of the nature of the "silent period" in muscle.

(a) Procaine 0·2% was infused intrathecally in one patient to the point where both knee and ankle jerks were abolished and sensation to pain and temperature was grossly reduced below

the 10th thoracic segmental level while proprioception, touch and muscle power were unaffected. This condition is thought to represent block of the gamma efferent fibres supplying the muscle spindle, with preservation of function in the alpha fibres supplying striated muscle. At this point of differential efferent block, myoclonic jerks and silent periods continued, indicating that neither of these phenomena were mediated by the gamma loop.

(b) The H reflex, which is elicited by stimulation of the posterior tibial nerve in the popliteal fossa and recorded from the calf muscles, is a method of testing the monosynaptic stretch reflex arc. It was found that H reflexes could be recorded during the "silent period" following myoclonus, indicating that the anterior horn cell is not being inhibited from above or via local segmental afferent pathways.

Discussion

It has been shown that the fall of myoclonus takes place during a period of electrical silence which occurs in the affected muscles following a myoclonic jerk. This is obviously a mechanism different from the physiological silent period which is seen after a tendon jerk or muscle twitch because it is of longer duration and outlasts the muscle jerk, and it cannot be overcome by active muscular contraction. The source of the silent period is unlikely to be afferent impulses from the muscle spindle as it persists after procaine block of the gamma efferent system. The anterior horn cell is not directly inhibited as it remains accessible to stimulation by H reflexes. It is possible that inhibition of internuncial cells may be mediated by some descending pathway, and thus prevents activation of the anterior horn cell by the corticospinal tract, but evidence from neurophysiological experiments suggests that the site of interference with motor function may be cerebral.

Arduini and Whitlock (1953) and Brookhart and Zanchetti (1956) have shown that stimulation of specific relay nuclei in the thalamus evokes a positive-negative spike response in the cat cortex, and have demonstrated that a descending volley in the corticospinal tract commences at the same time as the early positive component of the cerebral complex. Moreover, repetitive stimulation of these thalamic nuclei produces a series of cortical spikes increasing in amplitude, which has been called the "augmenting response", and, following this, the responsiveness of corticospinal neurones to direct stimulation is depressed for as long as 200 msec.

The phenomena of myoclonus are thus analagous to the experimental "augmenting response". The complexes recorded from the cortex are similar and in myoclonus there is also evidence of activity in descending motor tracts related to the cerebral spike. It is therefore possible that the "silent period" which is responsible for the lapse in posture after the myoclonic jerk may be explained by depression of cortical function as has been shown experimentally. This hypothesis supports the concept of Gastaut and Fischer-Wiliams (1959) who regard the myoclonic jerk as an incipient grand mal attack which has been terminated abruptly by a process of active inhibition.

To summarize, it is postulated that the basis of myoclonus in the patients studied is repetitive firing of thalamocortical neurones in response to a physiological afferent input. The ventrolateral nucleus of the thalamus is a specific relay nucleus from which the augmenting response has been obtained, and, as it is the intermediate station between the cerebellum and the cortex, this may account for the association of cerebellar deficit with this form of myoclonus which is enhanced by attempts at co-ordinated movement.

Summary

The falling attacks of myoclonus are associated with a lapse in postural control, seen as a "silent period" in the electromyogram, which may last up to 340 msec. after a myoclonic jerk.

H reflexes may be elicited during the silent period and it is not altered by gamma efferent block.

It is suggested that the silent period may be determined by a transient depression of cortical function similar to that which follows the "augmenting response" in the experimental animal.

Acknowledgements

This investigation was carried out in the Neurology Service of the Massachusetts Gen-

eral Hospital, Boston, U.S.A., under the direction of Dr R. D. Adams, while the author was the recipient of a Lilly Foreign Educational Fellowship and a grant from the Post-Graduate Medical Foundation, University of Sydney.

References

ARDUINI, A., and WHITLOCK, D. G. (1953). Spike discharges in pyramidal system during recruitment waves. *J. Neurophysiol.*, **16**, 430.

BROOKHART, J. M., and ZANCHETTI, A. (1956). The relation between electro-cortical waves and responsiveness of the cortico-spinal system. *Electroenceph. clin. Neurophysiol.*, 8, 427.

GASTAUT, H. (1954). *The Epilepsies.* Charles C. Thomas, Springfield, Illinois.

GASTAUT, H., and FISCHER-WILLIAMS, M. (1959). In *Handbook of Physiology*, vol. 1, edited by Field. Baltimore.

SYMONDS, C. P. (1954). Myoclonus. *Med. J. Aust.*, **1**, 765.

VISUAL MECHANISMS AND THE ELECTROENCEPHALOGRAM

ROSS DAVIS
Sydney

INTRODUCTION

SOME of the most striking features of the electroencephalogram in man are associated with the visual parts of the brain, for example, the alpha rhythm (8-14 cycles per second), "alpha blocking" and "photic driving". The cells and fibres of the visual system are ordered into well defined layers (occipital cortex, lateral geniculate, superior colliculus and retina), and the electroencephalographic waves are more dominant in the visual cortex. The problems remain as to how the cells are co-ordinated to produce the large potentials and how the rhythm is sustained.

Three hpyotheses have been formed relating to the latter problems. One supposition is that synchronizaton occurred as a result of the spread of current outwards from active cells via the intercellular spaces to affect the excitability of adjacent cells which results in the area oscillating in unison (Libet and Gerard, 1938, 1941).

The second postulate is that the mechanism of spread of activity is achieved by synaptic connections involving the concept that waves result from a summation of synaptic potentials and after-potentials generated in the dendrites and soma of the cells (see Purpura, 1959).

The third hypothesis postulated by Bremer (1953) combines the previous two and supposes that the neurones have the ability "to respond to humoral and to synchronous nervous stimuli by a regular rhythmical succession of bio-electric potentials, associated with oscillations of excitability and discharges of impulses".

The properties of the slow rhythms recorded in the lateral geniculate nucleus of the cat were investigated by P. O. Bishop and Davis (1960). The results were evaluated by P. O. Bishop, Burke, Davis and Hayhow (1960) who postulated that the normal alpha waves are due to intrinsically generated dendritic potentials synchronized by extracellular flows of currents. However, in the light of further histological and electrophysiological data on the lateral geniculate nucleus, the above hypotheses are now re-examined.

SLOW GENICULATE RHYTHMS

The slow rhythms, recorded by an electrode inserted stereotaxically into the lateral geniculate nucleus, have a predominant frequency between 6 and 15 c/s (mean 9 c/s) as seen in figure 16, a and i. Some irregularities are seen and fast activity is usually superimposed (figure 16, a); however, with the increase in depth of anaesthesia, both are reduced and a slowing of the predominant rhythm occurs. With the absence of the slow waves then, a volley initiated by electrical stimulation either at the optic nerve or optic radiation arriving at the geniculate nucleus can initiate the rhythm (figure 16, e and f). On the other hand, if the rhythm is already present, then the arriving volley appears to halt the rhythm and to trigger it in phase with the stimulus (figure 16, g). Similar results are obtained with an optic tract volley when the optic tract-geniculate synaptic transmission is blocked with the intra-arterial application of lysergic acid diethylamide (LSD) or as a result of post-tetanic delayed depression (PTDD) (figure 16, j).

The first cycle of these evoked rhythms is clearly distinguishable from the later waves. In the case of the soma being discharged by a volley resulting from stimulation of the optic nerve or optic radiation, there is a sequence of negative and positive after-potentials (figure 17 a, b, e and f). A similar sequence, although of less magnitude, is seen when the synaptic potential is recorded from the cell during the application of the blocking techniques using LSD or the state of PTDD. The slow geniculate rhythms are indistinguishable from the later waves produced by any of the above forms of activation (figure 16, g, i and j).

The origin of the slow waves was shown to

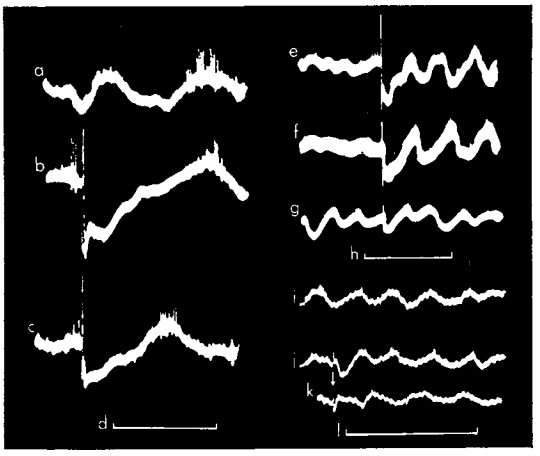

FIG. 16—Slow rhythms recorded by an insulated steel microelectrode inserted stereotaxically into the lateral geniculate nucleus of the cat. Traces *a-g* were recorded from the one site; *a*, slow rhythm with bursts of spike potentials on the negative waves; *b* and *e*, responses resulting from maximal stimulation to the contralateral optic nerve; *c*, *f* and *g*, responses resulting from stimulation to the optic radiation 1-2 m.m. below the cortical layers; *i*, *j* and *k* were obtained from another preparation during PTDD synaptic block, *i* and *j* being recorded at the same site in the lateral geniculate while *k* was recorded just above the nucleus in the optic radiation. *i*, rhythm; *j* and *k*, responses to maximal stimulation of the contralateral optic nerve (arrow indicates stimulus artifact in trace *k*). Each time scale refers to the three traces above it; *d*, 200 m.sec.; *h* and *l*, 0·5 sec. (Bishop and Davis, 1960).

be due to the activity of the principal neurones of the nucleus as there was a complete reversal of phase when the recording electrode was withdrawn from the lateral geniculate nucleus vertically up to the initial portion of the optic radiation, figure 16, j and k; figure 17). This evidence enables one to postulate that the slow rhythms have their origin in the soma-dentritic region of the neurone.

It appears then, that the geniculate cells' dendritic, and possibly part of the soma membrane potential does undergo oscillation, which can be initiated or modified by optic nerve activity. The problem is whether the cell has the property of auto-rhythmical activity, whether it is driven by neuronal circuits, or both.

Decisive evidence is not available, but much of the above data is in agreement with the first hypothesis. However, the determination of whether the principal neurones have auto-rhythmical properties will probably be delayed until the cell can be completely isolated from any possible continuing external activation. The problem could be assisted by the blocking of the non-optic activation of the cell, since in the absence of both eyes, the slow waves could still be recorded. The use of LSD as a blocking agent to tract-geniculate synaptic transmission was shown by Curtis and Davis (1961, 1962) to have no effect on the excitability of the geniculate cell. In addition it was shown by Curtis and Davis (1963) that other post-synaptic receptor sites which were sensitive to some choline esters applied locally were unaffected by 5-hydroxytryptamine (5-HT). 5-HT and LSD were also shown to have similar effects on the tract-geniculate synapse. This indicates limitation in the use of LSD as a technique for completely isolating the geniculate cell from activation other than that from the optic nerve. However, it is interesting to note that even though LSD did block the tract-geniculate synaptic transmission, it still did not stop the initiation of the geniculate cell slow waves by the optic

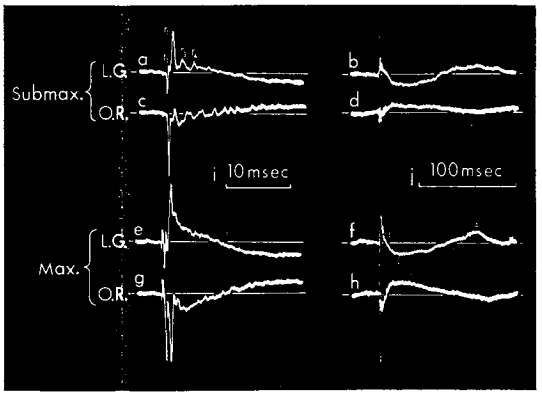

FIG. 17—Spike potentials and after-potentials recorded in the lateral geniculate nucleus (L.G.) in the optic radiation (O.R.) following single shocks applied to the contralateral optic nerve. t_1, presynaptic spike; r_1, r_3, r_4, post-synaptic spikes. Submaximal shock is 65% maximal for t_1. Maximal shock is maximal for whole optic nerve (t_1 and t_2). Time scale *i* refers to traces *a*, *c*, *e* and *g*, and time scale *j*, to traces *b*, *d*, *f* and *h* (Bishop and Davis, 1960).

nerve activation. Therefore, even though a specific blocking agent for the non-optic pathway geniculate synapses could be found, it is unlikely, in view of the above finding that this agent would completely block the effects of any non-optic pathway activity.

The effect of stimulation to the optic radiation undoubtedly does result in impulses travelling towards the lateral geniculate nucleus. However, there is histological and electrophysiological evidence to demonstrate that some impulses will be travelling in fibres which do synapse on geniculate cells (cortico-geniculate) apart from those impulses which will travel antidromically in fibres which originated in the geniculate cells (W. R. Hayhow, personal communication; Widen and Ajmone-Marsan, 1960; P. O. Bishop, Burke and Davis, 1962; D. R. Curtis and R. Davis, unpublished observations). Thus one cannot justifiably postulate that the evoked geniculate slow rhythm was initiated by a true antidromic volley, as synaptic activation is also in process.

The second suggestion implying re-activation of the geniculate cells by neuronal circuits would mean that the slow waves recorded are composed of summed synaptic potentials and after-potentials. The presence of an after-potential could be deduced because, as is seen under these conditions of anaesthesia, bursts of spikes do occur at high frequency on the negative peaks of the slow waves (figure 16, a, b and c). As the site of contact for the majority of the synaptic terminals is on the dendrites, it would be difficult to distinguish the presence of recurring synaptic potentials from the potentials of an auto-rhythmical dendritic membrane. It is unlikely, however, that the geniculate cell forms a link in any neuronal circuits as the rhythm can be initiated by a tract volley when the tract-geniculate synaptic transmission is blocked. The most probable mechanism for this second hypothesis could be that the principal cell is re-activated from a non-optic source or "pacemaker" without the necessity of involving the geniculate cell in a neuronal circuit. This mechanism would also suggest that the optic tract volley would not only activate the geniculate cell but would also start or trigger the "pacemaker". The supposition of a "pacemaker" is further supported by the fact that the geniculate slow rhythms were recorded when both eyes were removed. Further evidence in agreement with the extra-geniculate "pacemaker" concerns the experiment of Claes (1939) on the unanaesthetized encéphale isolé preparation of the cat. Here the spontaneous electrical activity of the striate cortex showed the same characteristic changes between the sleeping and waking states, as does the activity of other cortical areas. However, there is no well marked periodicity corresponding to the human alpha rhythm, and no consistent difference between the activity in darkness and in light, though onset and cessation of illumination causes bursts of large waves.

The existence of a "pacemaker" could account for the initiation, frequency, and persistence of the slow waves as well as the major factor of synchronization of the geniculate cells. The location of a possible "pacemaker" could be in the mid-brain, and is suggested by the results of Suzuki and Taira (1961) who showed that the post-synaptic response of the geniculate neurones is affected by stimulation of the mesencephalic reticular formation. This in turn supports the earlier work of Hernández-Peón and his group (1955, 1956, 1957) who observed that the photically evoked potential of the lateral geniculate was greatly reduced in amplitude by stimulation of the reticular formation and that a similar attenuation of the geniculate-evoked potential occurred during an animal's attention to acoustic or olfactory stimuli.

It is important to note that it is the combination of the orderly arrangement of cell processes and the organization of cells into laminae, with the synchronization of cellular activity in the lateral geniculate nucleus that allows the response to be recorded so distinctly.

Alpha Rhythm

The similarity between the geniculate slow waves and the alpha rhythm recorded in the visual cortex is striking. It is interesting to note the results of Bartley and G. H. Bishop (1933), Bartley, O'Leary and G. H. Bishop (1937) and Bartley (1942) when recording from the visual cortex of the cat under conditions of experimental manipulation. As a result of stimulating the retina or optic nerve, the initial cortical response was followed by a triphasic sequence

lasting about ten times as long as the first. "The latter (tri-phasic) component", described by Bartley (1942), "may repeat forming a train of waves, which to all appearances, is a series of the well-known alpha waves. A strong stimulus drove the cortex by instituting this rhythm wholely similar to, but out of tune with the pre-existing alpha wave, sometimes wholely supplanting them. It is therefore evident that the peripherally induced cortical activity and the pre-existing waves occupy the same groups of cells in the same way, and so it could be said that a stimulus institutes alpha rhythm." Since the geniculate cells, following a single optic nerve stimulus, generate rhythmical potentials with bursts of spikes on the negative waves, it is suggested that these bursts of impulses, as a result of being carried up the optic radiation could, in turn, be the mechanism for initiating, perpetuating and synchronizing this cortical rhythm.

Acknowledgements

The investigation of the slow geniculate rhythms was carried out by the author in collaboration with Professor P. O. Bishop at the Brain Research Unit, Department of Physiology, University of Sydney. The author was then Research Fellow of the Ophthalmic Research Institute of Australia.

Acknowledgement is also made to Miss M. Lane for secretarial, and to Mr B. McGee, for photographic assistance.

Acknowledgement is also made to Dr C. J. Cummins, Director-General of Public Health and State Psychiatric Services, for his permission to have this paper published.

References

BARTLEY, S. H. (1942). Visual sensation and its dependence on the neurophysiology of the optic pathway. *Biological symposia, visual mechanisms*, 7, 87-106.

BARTLEY, S. H., and BISHOP, G. H. (1933). Factors determining the form of the electrical responses from the optic cortex of the rabbit. *Amer. J. Physiol.*, **103**, 173-184.

BARTLEY, S. H., O'LEARY, J., and BISHOP, G. H. (1937). Differentiation by strychnine of the visual from the integrating mechanisms of optic cortex in the rabbit. *Amer. J. Physiol.*, **120**, 604-618.

BISHOP, P. O., BURKE, W., and DAVIS, R. (1962). Single-unit recording from antidromically activated optic radiation neurones. *J. Physiol.*, **162**, 432-450.

BISHOP, P. O. and DAVIS, R. (1960). Synaptic potentials, after-potentials and slow rhythms of lateral geniculate neurones. *J. Physiol.*, **154**, 514-546.

BREMER, F. (1953). Some problems in neurophysiology. London Univ. Press, London.

CLAES, E. (1939). Analyse oscillographique de l'activité spontanée et sensorielle de l'aire visuelle corticale chez le chat non anesthésié. *Arch. int. Physiol.*, 48, 181-237.

CURTIS, D. R., and DAVIS, R. (1961). A central action of 5-hydroxytryptamine and nor-adrenaline. *Nature*, **192**, 1083-1084.

CURTIS, D. R., and DAVIS, R. (1962). Pharmacological studies upon neurones of the lateral geniculate nucleus of the cat. *Brit. J. Pharmacol.*, 18, 217-246.

CURTIS, D. R., and DAVIS, R. (1963). The excitation of lateral geniculate neurones by quaternary ammonium derivatives. *J. Physiol.*, **165**, 62-82.

HERNÁNDEZ-PEÓN, R. (1955). Central mechanisms controlling conduction along central sensory pathways. *Acta Neurol. Latinoamer.*, **1**, 256-264.

HERNÁNDEZ-PEÓN, R., GUZMÁN-FLORES, C., ALCARAZ, M., and FERNÁNDEZ-GUARDIOLA, A. (1957). Sensory transmission in visual pathway during "attention" in unanaesthetized cats. *Acta Neurol. Latinoamer.*, **3**, 1-8.

HERNÁNDEZ-PEÓN, R., SCHERRER, H., and VELASCO, M. (1956). Central influences on afferent conduction in the somatic and visual pathways. *Acta Neurol. Latinoamer.*, **2**, 8-22.

LIBET, B., and GERARD, R. W. (1938). Automaticity of central neurones after nicotine block of synapses. *Proc. Soc. exp. Biol. Med.*, **38**, 886-888.

LIBET, B., and GERARD, R. W. (1941). Steady potential fields and neurone activity. *J. Neurophysiol.*, **4**, 438-455.

PURPURA, D. P. (1959). Nature of electrocortical potentials and synaptic organizations in cerebral and cerebellar cortex. *Internat. Rev. Neurobiol.*, **1**, 47-163.

SUZUKI, H., and TAIRA, N. (1961). Effect of reticular stimulation upon synaptic transmission in cat's lateral geniculate body. *Jap. J. Physiol.*, **11**, 641-655.

WIDEN, L., and AJMONE-MARSAN, C. (1960). Effects of corticopetal and corticofugal impulses upon single elements of the dorsolateral geniculate nucleus. *Exp. Neurol.*, **2**, 468-502.

FURTHER OBSERVATIONS OF THE SUPRAPINEAL ARACHNOID BODY

G. C. T. KENNY*
Melbourne

IN 1940, Le Gros Clark described in two individuals a curious tuft of the arachnoid membrane of the human brain occurring beneath the junctional area of the great cerebral vein (great vein of Galen) and the straight sinus, and for descriptive convenience termed it the "suprapineal arachnoid body" because of its position above and behind the pineal body. This formation, which was traversed by the nervus conarii, bore a general resemblance to a single large arachnoid granulation of the usual type (Pacchionian body) but exhibited certain peculiar features. Structurally, it possessed an unusually dense fibrous stroma arranged in the form of a reticulum within whose spaces was found a rich plexus of sinusoidal blood-vessels and several large interconnecting blood sinuses, while at its summit it was adherent to the dura mater forming the floor of the straight sinus at its commencement. Le Gros Clark observed that its intrinsic structure recalled that of erectile tissue, though he was unable to find evidence of elastic or plain muscle tissue, and suggested from its anatomical appearance and disposition that the body "may provide a ball-valve mechanism whereby the venous return from the great vein of Galen is regulated and controlled". In one of the specimens he reported, the channels of the plexus were filled with blood, in the other the sinuses were partly empty and collapsed. No further observations upon the suprapineal arachnoid body appear to have been recorded in the literature.

At the time of his description, Le Gros Clark remarked that it was necessary to examine more material in order to determine the constancy of the body and mentioned that he had himself seen it histologically in four specimens. In view of the possible consequences of such a vascular mechanism, it seemed important that this should be done, particularly as reference is now made to its suggested function in a well-known textbook of anatomy as follows:

"This body, which contains a sinusoidal plexus of blood-vessels, is believed to become engorged from time to time and may then act as a ball valve mechanism to control the outflow from the great cerebral vein and so to influence the secretion of cerebrospinal fluid by the choroid plexuses of the lateral ventricles."

The findings reported here, obtained from thick celloidin sections of three additional specimens, represent part of a further investigation into the occurrence of the suprapineal arachnoid body and the vascular plexus which it is said to contain. In two of the subjects, both female, aged thirty-two years and seventy-four years, death was due respectively to uraemia and pulmonary embolism; the third, a male aged ten years, died as the result of a subdural haemorrhage of traumatic origin.

In all specimens, the suprapineal arachnoid body was seen as an especially prominent mass and blood corpuscles were observed within the meshes of its stroma. In two individuals the meshwork was, as before, partly empty, but in the third, whose death resulted from a subdural haemorrhage, it was once again filled. In this latter preparation, a plexus of well defined channels completely occupied by blood was clearly evident (Fig. 18a), but because of the nature of death in this case, the question arose as to whether these channels were sinusoidal structures lined by a "single-celled layer of endothelium" or spaces filled with extravasated blood, particularly as vascular congestion and some extravasation occurred elsewhere in the sections. Careful examination of the material furnished evidence in favour of the former interpretation. Not only were these channels distinctly confined and thoroughly filled, but a

* This work is supported by a research grant from the National Health and Medical Research Council of Australia.

FIG. 18—Sagittal section of the suprapineal arachnoid body. Stained by haematoxylin and eosin. A. x 10, *c.* superior vermis of cerebellum; *cc.* splenium of corpus callosum; *g.* great cerebral vein; *s.* straight sinus; *s.p.* suprapineal body displaying portion of the plexus. B x 400. Channel belonging to the plexus exhibiting both a confined appearance and peripherally situated nuclei. C. x 520. Channel of the plexus showing thin lining.

thin lining and a single layer of nuclei, presenting the appearance of an endothelium, could be distinguished along their margins (Fig. 18b and c). Thus, there is little doubt as to their truly vascular character.

The observations made here concerning the suprapineal arachnoid body accord with those of Le Gros Clark. The functional significance of the body, however, still remains obscure.

Acknowledgements

I should like to thank Professor L. J. Ray for his helpful interest in this communication, and also to express my appreciation to Mr E. Matthaei and Mr R. Oldfield for the care they have taken in the preparation of the photomicrographs.

References

CLARK, W. E. Le Gros (1940). A vascular mechanism related to the great vein of Galen. *Brit. med. J.*, vol. i, 476.

——— (1940a). The nervous and vascular relations of the pineal gland. *J. Anat.* (*Lond.*), 74, 471.

JOHNSTON, T. B., DAVIES, D. V., and DAVIES, F., editors (1958). *Gray's Anatomy, Descriptive and Applied.* 32nd edition, London, Longmans, 848.

THE PROBLEMS OF SUBDURAL GAS AFTER PNEUMOENCEPHALOGRAPHY

E. GRAEME ROBERTSON
Melbourne

THE significance of subdural gas has been a subject of controversy over the years. Some believed that gas gained the subdural space from the supratentorial subarachnoid space through tears in the arachnoid membrane, by tearing of the arachnoid sheaths around veins passing to the longitudinal sinus or in the region of a meningocerebral cicatrix. Others contended that it was, in reality, a technical error due to introduction at the point of the lumbar needle, a viewpoint which the present writer believed to be correct, simply because when the volume was large, subdural gas could be seen in the posterior fossa and traced upwards from the foramen magnum to the vertex.

The frequency of subdural filling found by different authors varied enormously. Davidoff and Dyke found it in 7% of cases, while Hemmingson found it in 15·4% of patients whose films were taken immediately after the introduction of gas and in 69% of patients whose films were taken on the following day. There is no doubt that subdural gas may be seen only in 24 hour films; and since the upward passage of gas throughout the whole subdural space is very rapid, the slow collection of subdural gas, showing only in delayed films, seemed against any theory of insufflation into the lumbar subdural space.

However, a reconciling clue was found in axial films taken in recumbency immediately after introduction of gas, with one or other side of the head uppermost. In standard films taken with brow, occiput or one or other side of the head uppermost, subdural gas is spread out in an extensive, but thin, layer, which causes only a diffuse darkening of the films, and, having shelving edges, it is not detectable. If, however, in any of these postures, the tube is rotated through a right angle, the central ray becomes co-axial with the extensive but shallow collection and hence narrow, dense shadows result (figure 19). Finally, if axial and lateral films be taken with the vertex uppermost, gas will throw a characteristic shadow following the vault of the skull above and having a more or less horizontal, straight edge below. If these less usual immediate views had not been taken, the subdural gas would have been recognized only in the delayed films which are commonly taken because they reveal subdural gas, that is, lateral and axial films with the vertex uppermost. Thus, it seemed that, at least in most instances, gas was introduced into the subdural space at the point of the needle.

The bevel of the needle may have incompletely pierced the posterior or anterior arachnoid membrane, so that fluid may escape through the portion within the subarachnoid space, while gas may be injected into the subdural space, or into both spaces. The arachnoid membrane may move about in relation to the bevel. If the arachnoid has been pierced previously, fluid may escape into the subdural space (as when the patient suffers from post-lumbar puncture headache) and the arachnoid may be so flaccid that it is pushed ahead of a newly introduced needle. Hence fluid may be evacuated from the subdural space and gas injected into it.

CLINICAL SIGNIFICANCE OF SUBDURAL GAS

McConnell reported that he found subdural gas in 80% of 34 encephalograms of patients suffering from post-traumatic disturbances. In only five was there no subdural gas: in three it was seen in immediate films, while in 26 it was seen only in delayed films. At operation he found subdural fluid in 27 cases, and the removal of this fluid relieved the patient's symptoms in approximately 80% of cases. Indeed, he believed that the syndrome alone was a sufficient reason for operation. As a result of these experiences, he ascribed post-traumatic symptoms to fluid which had gained the sub-

dural space through tears in the arachnoid membrane caused at the time of the initial injury.

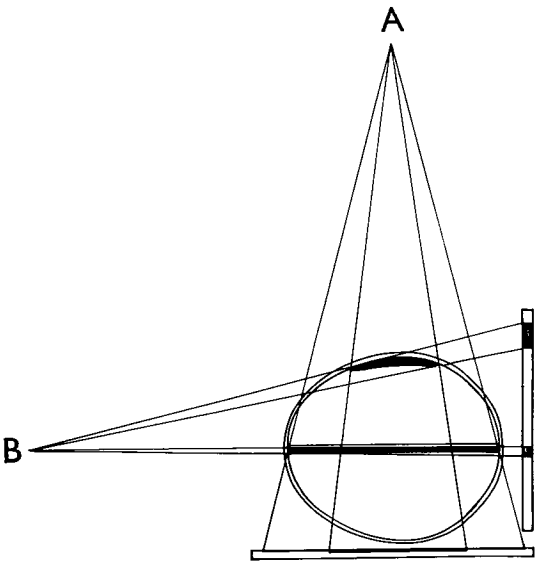

FIG. 19 A

FIG. 19 B

FIG. 19—To illustrate the difference between standard projections, and films taken at right angles to these, in showing subdural collections.

(a) The head is in the ordinary recumbent lateral position. Thin but extensive collections of gas fail to cast recognizable shadows in a lateral view (A), while in an axial view the rays pass along the long axes of the collections (B), hence dense shadows result.

(b) A film taken in projection B.

Luyendijk (1959) supports McConnell's findings, but suggests that a "transudation phenomenon" rather than a tear in the arachnoid is the cause. In the post-traumatic syndrome, he states, pores are present in the arachnoid, and subarachnoid air passes through these pores and can be found 24 hours later in the subdural space. Like McConnell he finds that ample drainage of subdural and subarachnoid fluid usually relieves the complaints. In the majority of patients complete recovery followed.

For some time the present writer has believed that transudation of gas and fluid may occur through the arachnoid membrane in some cases, but the finding of subdural fluid has been so inconsistent, and the state of the patient so unrelieved by operations, that we have abandoned the procedure, in chronic cases.

The matter was therefore of sufficient importance to merit further study. Two methods were used, firstly analyzing the subdural filling in 200 consecutive encephalograms carried out for this purpose, and secondly, by making burr holes in appropriate cases, this minor series extending over a much longer period of time.

Subdural Filling in 200 Pneumoencephalograms

More gas (about 100 mls.) was used than usual, hence space-occupying lesions and children were excluded and the otherwise consecutive series of investigations was not continued beyond 200. Frank subdural haematomas gave an entirely different picture (as will be recounted later) and are not included in this series.

Gas was found to be present in the subdural space of 67 patients, that is, in 33·5%. It was found in immediate films in 51, and in delayed films (taken 24 hours after introduction) in 16.

Table I compares the incidence of immediate and delayed fillings in those suffering from post-traumatic symptoms, with the remainder of the group.

Thus a delayed collection of gas was far commoner in traumatic than in non-traumatic cases. However, the percentages in which immediate subdural gas was found appear comparable in the two groups, while the greater percentage of subdural fillings in traumatic cases was largely due to delayed filling. Indeed,

TABLE I

Subdural Filling in Traumatic and Non-traumatic Groups

40 POST-TRAUMATIC SYNDROMES
Subdural gas found in 21 (52·5 %).
Subdural gas found in immediate films in 15 (i.e. 71% of 40)
(of these a further increase occurred over 24 hours in 3 patients)
Subdural gas in delayed films alone in 6 (29%).
Percentages added only to facilitate comparison with next group
160 NON-TRAUMATIC CASES
Subdural gas found in 43 (27%).
Subdural gas in immediate films in 38 (88% of 43) (none showed a subsequent increase).
Subdural gas in delayed films alone in 5 (12%).

except in one case, the delayed collections in non-traumatic cases was so small that it might have been missed in immediate films. (Axial films with one side of the head uppermost were sometimes omitted in non-traumatic cases, being inessential for diagnosis.)

Thus, it seems probable that gas may gain the subdural space in delayed fashion from the intracranial subarachnoid space, especially after trauma has occurred. An increase over 24 hours occurred in some traumatic cases, suggesting that both introduction at the point of the needle and intracranial entry may occur, as might be expected in a proportion of such cases.

In summary, this analysis suggests that in most instances (even in the traumatic group) gas enters the subdural space at the point of the needle; while in some instances (usually following trauma) it may gain access from the intracranial subarachnoid space. Poor techniques and the introduction of large volumes increase the percentage of subdural fillings, while the failure to recognize immediate filling will increase the apparent percentage of delayed fillings.

EXPLORATION BY BURR HOLES

Twenty-six patients with post-traumatic symptoms were investigated by pneumoencephalography and the making of burr holes.

In these instances, investigation was usually undertaken because of headache, sometimes combined with giddiness (often rather dizziness or light-headedness) and usually associated with difficulty in concentration and with irritability, persisting after mild or severe head injury. It would take too long to recount these histories; hence let it be said that the question of compensation existed in some form or other in all instances, that the headache often had features which made it difficult to differentiate between an organic and psychogenic type, and that it always seriously interfered with occupation. The patients almost invariably were tense and apprehensive and reacted badly during encephalography. Whether subdural fluid was found on exploration or not, they claimed improvement and perhaps refused a second burr hole, and thus thwarted any plan to obtain staged information. Almost invariably, however, the symptoms recurred after leaving hospital.

The results are so varied that brief presentation of all the combinations and mutations is impossible. However, division into five groups facilitates description:

(a) Subdural gas in delayed films only—10 cases.

In 7 varying volumes of subdural fluid were evacuated, while in 3 none was found.

Illustrative cases:

CASE I. Pneumonencephalography, bilateral delayed collections of subdural gas. Right burr hole, 7 days later, 5 mls. yellow fluid evacuated. Left burr hole, 7 months later, no fluid. Pneumonencephalography, 3 days later, large delayed collections.

CASE II. Pneumonencephalography, left sided delayed collections. Bilateral burr holes, 4 days later, large volumes of fluid on each side.

CASE III. Pneumoencephalography, bilateral immediate collections. Left burr hole, 9 months later, no fluid. Pneumoencephalography next day, bilateral delayed collections. Bilateral burr holes, 3 days later, large volumes of fluid on each side.

CASE IV. Pneumoencephalography, bilateral delayed collections. Bilateral burr holes, 5 days later—right, 110 mls. fluid; left, 90. Patient improved but symptoms returned. Pneumoencephalography, 9 months later, right sided delayed collection. Right sided re-exploration, no excess of fluid.

These illustrate the bewildering variability of the results, and show that delayed subdural collection is not a reliable indication of the presence of subdural fluid. In contrast to subarachnoid fluid, subdural fluid is yellow in

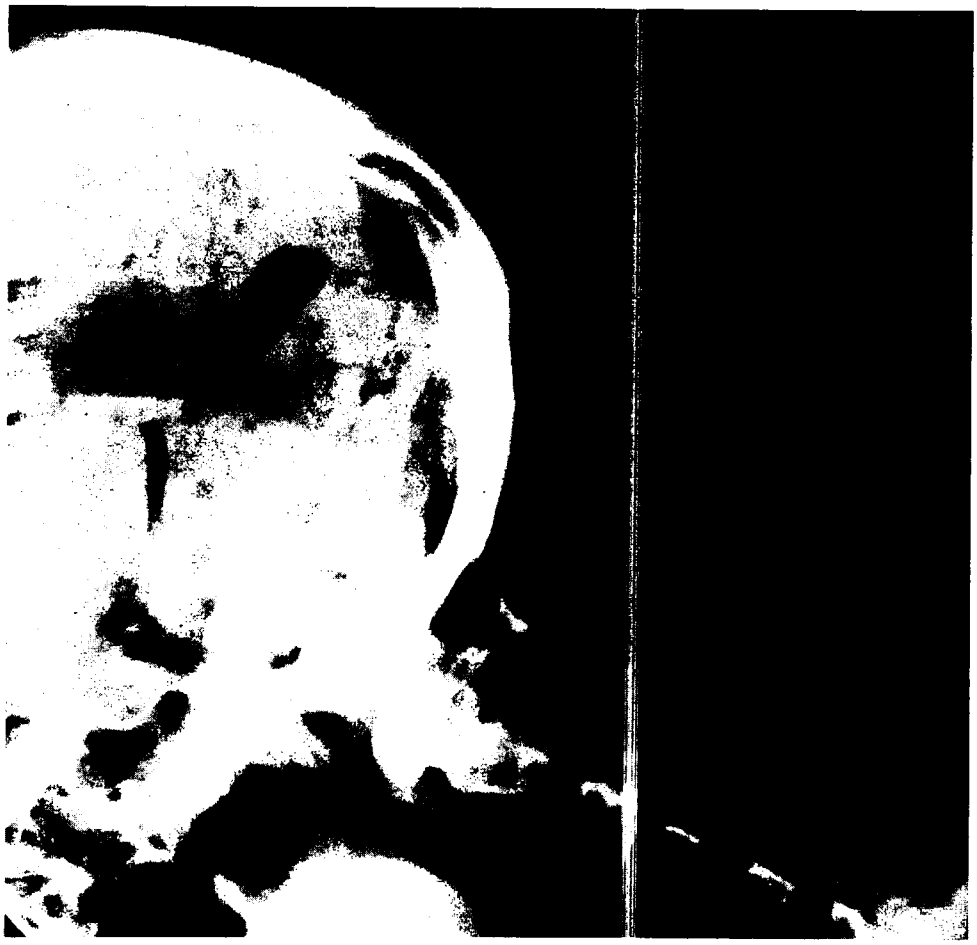

FIG. 20 A

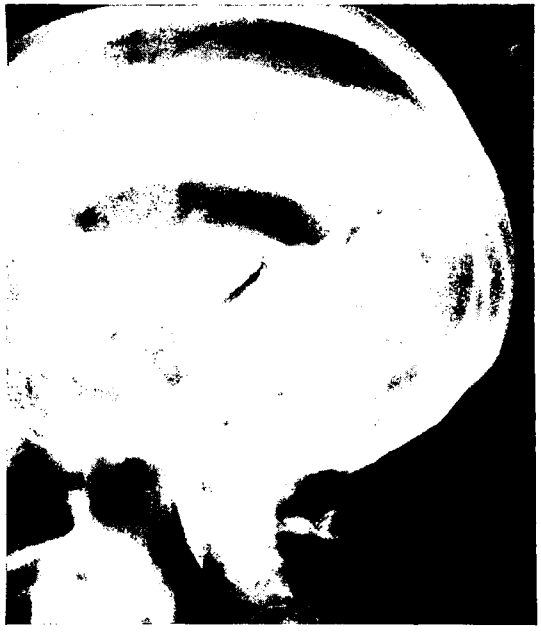

FIG. 20 B

FIG. 20—CASE V. Subdural gas, passing through the posterior fossa and forming "immediate" collections at the vertex.

(a) Cervical spinogram, with neck fully flexed. Note subdural collection in posterior fossa and below tentorium, with superimposed sulcal shadows.

(b) After the head was extended, the subdural gas was seen at the vertex.

(c) Subsequent antero-posterior film with brow up to show absence of indication of subdural gas which is now spread extensively below the frontal bones.

(d) Standard lateral film, again failing to show the extensive collections below falx and inner table of uppermost part of skull. One axial film was similar to that shown in figure 1b, although less subdural gas was present.

(e) "Immediate" axial film with head erect. Note the horizontal lower border of shadows of gas (not considered to be a fluid level), and the "suspending" vessel lateral to the sagittal sinus.

(f) Lateral view with head erect.

colour and contains more protein, 2,000 mgm. per cent being the highest figure in the series.

(b) Subdural gas increased over 24 hours in 5. Subdural fluid was found in 2; in 3, none.

(c) Immediate subdural gas was found in 6. No subdural fluid was found in 2. In 4, large volumes of subdural fluid was found, and in 3 of these the subdural gas could be traced upwards through the posterior fossa.

CASE V. An alcoholic man had received many injuries, some to the head, culminating in multiple stab wounds to chest inflicted by his *de facto* wife. Signs sugesting mixed upper and lower motor neurone lesions were found in his remaining arm, and both plantar responses were extensor. It was decided to do cervical myelography, with the neck fully flexed (Fig. 20a), as well as encephalography. In the inclined position of the head gas collected in the subdural space over the cerebellum, and when the head was extended the gas rapidly rose to the vertex (Fig. 20). Figures 2c and d are included to show

FIG. 20 C

FIG. 20 E



FIG. 20 D

FIG. 20 F

the absence of any indication of subdural gas in axial and lateral views taken in recumbency. Figures e and f show typical appearance of subdural collections in axial and lateral views with the vertex uppermost. Burr holes were made 7 days later, slightly yellow fluid squirting out from the left side, whereas on the right no fluid was found.

This group suggests that the presence of gas in the subdural space may stimulate the outpouring of yellow fluid into the space. A child, who was not known to suffer from trauma, and therefore not included in this group, was found to have a subdural "hygroma" when a cortical biopsy was made seven days after pneumoencephalography. Gas had passed into ventricles and subarachnoid space and a very large volume of subdural gas was seen in the posterior fossa during introduction and in films taken in recumbency. The large volume of gas in the subdural space at the vertex may have allowed the cortex to drop and so to rupture the arachnoidal venous sheaths passing from the cortex to the longitudinal sinus, and with escape of cerebrospinal fluid into the subdural space.

It seems highly unlikely that subdural hygromas were present before pneumography in all these cases. The lower borders of the shadows were the same as those in which no fluid was found. Although often described as a fluid level, the evidence suggests that this merely marks the level of separation of arachnoid and dura.

(d) Fluid evacuated before pneumography—3 patients.

No gas gained the subdural space in one instance.

In one, gas was seen only in delayed films, while in the remaining case the volume increased over 24 hours. Both were re-explored, fluid being found in one and none in the other.

(e) No subdural gas or fluid initially, while 3 months later large bilateral accumulations of fluid were found in one patient.

(f) No gas and no fluid was found three months after a heavy blow to the head. Angiography showed displacement of mid-line vessels and a burr hole revealed discoloured brain. This merely suggests that the "post-traumatic syndrome" may have other causes.

Finally, it is of interest to note that no subdural gas has been seen in a number of cases with subacute and chronic subdural haematomas (not included in this series). Massive ventricular displacement, dilatation of the contra-lateral ventricle, and particularly the temporal horn, and a failure of gas to pass into the ipselateral subarachnoid space have been constant characteristics. The mechanism of formation of such haematoma is probably quite different from that of the "hygromas". Honor Smith and Crothers have reported that *very* large injections of gas in childhood may lead to tearing of veins and surrounding arachnoid sheaths extending from the cerebral cortex to the region of the sagittal sinus, with the formation of large haematomas or collections of blood-stained fluid which need evacuation.

In summarizing these variable findings it may be said that

(a) Subdural fluid may be found when subdural gas presents only, or in increased volume, in 24 hour films, but not in all instances. Fluid is more likely to be found soon after the introduction of gas than after a long interval.

(b) Subdural gas may accumulate when no fluid was previously present, as shown by a preliminary burr hole.

(c) Subdural fluid may be found even when no subdural gas was seen nor fluid found at an earlier date.

(d) Burr holes may evacuate xanthochromic fluid, when subdural gas is seen in large volumes in immediate films, even in patients without a history of trauma.

Discussion

The following may be suggested to explain most of the observations recorded throughout the paper. It is, however, to be remembered that it is only hypothesis.

(i) Gas may commonly gain the subdural space at the point of the lumbar puncture needle and, in this case, is no indication of the presence of a preceding subdural hygroma.

(ii) The presence of gas in the subdural space may provoke the outpouring of a yellow fluid, with increased protein, which might result from arachnoidal transudation or exudation. However, the effect is not consistent.

(iii) In some traumatic cases gas gains the subdural space within the cranium. The arachnoid membranes may have been rendered abnormal by trauma, so that is is no longer a barrier to gas and fluid.

Neurosurgeons have reported "weeping" of fluid through the arachnoid after trauma (Naffziger) or when the intracranial pressure is high (von Storch and Buermann). The latter authors were unable to force gas under pressure through the normal arachnoid. Trauma might conceivably cause persistent abnormality in the arachnoid, which in turn might lead to transudation or secretion of fluid, the volume of which might vary with the intracronial conditions pertaining at the time. Such an abnormality of the arachnoid might transmit gas from the subarachnoid to the subdural space. Once gas has gained the subdural space, by whatever route, it might stimulate an outpouring of yellow, highly proteinous fluid. Hence, even in traumatic cases, gas is not a definite indication of a previous hygroma, although one may have existed since an arachnoid which allows transudation of gas might also transmit fluid. Further, fluid may well enter the subdural space through a traumatic tear in the arachnoid, but, unless placed very fortunately (depending upon the posture of the head) it is very unlikely that such a tear would transmit much gas during and after pneumoencephalography. We have no knowledge of how long tears in the arachnoid remain unhealed.

The matter remains unsolved, as also does the clinical problem. The illness is a complex one, due basically, it is believed, to general neuronal damage, probably with vascular factors in the early stages, and perhaps to a persistently abnormal arachnoid in some patients, but with an intermixed psychogenic component, based upon fears of damage to the brain (often contributed to by injudicious remarks of acquaintances), immediate financial worries, and dread of future incapacity with a natural desire to protect himself and his family by obtaining full compensation. The proportions of these components vary, but the presenting symptoms seem much the same in all cases, perhaps because they are due to inefficient cerebration, whether induced by organic disease, or preoccupation with worries.

Headache may well be a response to labouring cerebral functions of either causation, or to oversensitiveness to the head in general, or of the region originally injured.

Summary

(i) Gas usually enters the subdural space at the point of the lumbar puncture needle.

(ii) Gas may gain the subdural space within the skull after head injury.

(iii) Trauma may lead to abnormal permeability of the arachnoid, so that fluid or gas may pass through it, but a delayed collection of gas does not necessarily indicate a preceding or permanent collection of fluid. Fluid may pass through a traumatic tear in the arachnoid, but it is unlikely that its position would allow large volumes of gas to do so.

(iv) Whatever the route followed, subdural gas may in some instances stimulate the outpouring of characteristic subdural fluid. Thus, its presence is no indication of the presence of a preceding collection of fluid.

(v) An alternative method may be tearing, during pneumoencephalography, of arachnoidal venous sheaths as they cross the subdural space. However, it would be difficult to explain how this process begins, except in cases where large volumes ascend in the subdural space from the lumbar region. Nor does it so readily explain variable hygromas—present sometimes and not at others.

(vi) Pneumoencephalography is of no value in diagnosis of subdural "hygromata". It may be pointed out that this conclusion, forgotten meanwhile, was stated in classical papers written in 1938 and 1939 by von Storch and Munro and von Storch and Buermann.

Acknowledgements

I would like to express my gratitude to my neurosurgical colleagues, Mr R. S. Hooper, Mr J. Bryant Curtis and Mr R. Lowe, for their co-operation in exploring the subdural spaces.

References

Davidoff, L. M., and Dyke, C. G. (1937). *The Normal Encephalogram.* Lea and Febiger, Philadelphia.

Hemmingson, H. (1940). Roentgenologic investigations of the intracranial subdural space with a view to revealing the presence of subdural adhesions. *Acta Radiol. (Stockh.)*, **21**, 379.

LUYENDIJK, W. (1959). The post-traumatic syndrome and the transudation phenomenon of the arachnoid membrane. In Recent Neurological Research. Elsevier, Amsterdam.

MCCONNELL, A. A. (1953). On certain sequelae of closed head injuries. The pathological basis of the "Post-traumatic Syndrome". *Brain*, **76**, 473.

MCCONNELL, A. A. (1953). Subdural air after pneumoencephalography. *Brain*, **76**, 485.

NAFFZIGER, H. C. (1924). Subdural fluid accumulations following head injury. *J. Amer. Med. Ass.*, **82**, 1751.

SMITH, H. V., and CROTHERS, B. (1950). Subdural fluid as a consequence of pneumoencephalography. *Pediatrics*, **5**, 375.

VON STORCH. T. J. C., and BUERMANN, A. (1939). Subdural shadows in pneumoencephalograms. *A.M.A. Arch. Neurol.*, **42**, 810.

VON STORCH. T. J. C., and MUNRO, D. (1938). Encephalography in the diagnosis of subdural haematomas. *New Engl. J. Med.*, **218**, 6.

AUSTRALIAN ASSOCIATION OF NEUROLOGISTS

LIST OF MEMBERS

COUNCIL MEMBERS

President:

DR E. GRAEME ROBERTSON, M.D., F.R.C.P. (Lond.), F.R.A.C.P., F.C.R.A. (Hon.) (Foundation Member)
33 Collins Street, Melbourne, Vic.

Present Appointments:

Honorary Neurologist, Royal Melbourne Hospital, Melbourne.
Honorary Neurologist, Royal Children's Hospital, Melbourne.
Honorary Neurologist, Royal Women's Hospital, Melbourne.

Honorary Secretary:

DR JOHN A. GAME, M.D., M.R.A.C.P. (Foundation Member)
61 Collins Street, Melbourne, Vic.

Present Appointments:

Honorary Neurologist, Alfred Hospital, Melbourne.

Honorary Treasurer:

DR JOHN J. BILLINGS, M.D., M.R.C.P. (Lond.), F.R.A.C.P. (Foundation Member)
55 Collins Street, Melbourne, Vic.

Present Appointments:

Honorary Neurologist, St. Vincent's Hospital, Melbourne.
Physician, Victorian Eye and Ear Hospital, Melbourne.
Consultant Neurologist, Queen's Memorial I.D. Hospital, Fairfield, Vic.

Councillors:

DR GERALD CAREW MOSS, M.B., B.S., B.A., M.R.C.P. (Lond.), F.R.A.C.P. (Foundation Member)
48A Irvine Street, Peppermint Grove, Perth, W.A.

Present Appointments:

Full-time Physician and Neurologist, Mental Health Service, Perth, W.A.
Consulting Physician and Consulting Neurologist, Royal Perth Hospital, W.A.
Visiting Neurologist, Department of Repatriation, Perth, W.A.

DR LEONARD R. RAIL, M.B., B.S., M.R.A.C.P.
143 Macquarie Street, Sydney, N.S.W.

Present Appointments:

Honorary Neurologist, Royal Alexandra Hospital for Children.
Honorary Electro-encephalographer, Royal Prince Alfred Hospital, Sydney.
Honorary Consultant Neurologist, Northcott Neurological Centre and Renwick Infants Hospital

DR GEORGE SELBY, M.B., B.S., M.R.C.P. (Lond.), F.R.C.P. (Edin.), M.R.A.C.P
North Shore Medical Centre, 66 Pacific Highway, St. Leonards, N.S.W.

Present Appointments:

Hon. Asst. Physician in Charge of Neurology Clinic, Royal North Shore Hospital.
Consultant Neurologist to Mater Hospital, Hornsby and District Hospital.
Consultant Neurologist to Northcott Neurological Centre.
Lecturer in Neurological Anatomy, Sydney University.

ORDINARY MEMBERS

DR JOHN ALLSOP, M.B., B.S., M.R.A.C.P.
Royal Prince Alfred Hospital, Camperdown, N.S.W.

Present Appointments:

Consulting Neurologist, Rachel Forster Hospital.
Assistant Physician, Royal Prince Alfred Hospital, Camperdown.
Clinical Neurologist, Lidcombe State Hospital.
Consultant Neurologist, Northcott Neurological Centre.
Consulting Neurologist, Cerebral Surgery and Research Unit, Callan Park.
Consultant Neurologist, Sutherland Shire District Hospital, Caringbah.

DR L. S. BASSER, M.B., B.S., M.R.C.P. (Lond.), M.R.A.C.P.
193 Macquarie Street, Sydney, N.S.W

Present Appointments:

Consultant Neurologist and Administrator, Northcott Neurological Centre.
Honorary Electro-encephalographer, Sydney Hospital.

DR JOHN D. BERGIN, M.B., Ch.B. (N.Z.), M.R.C.P., M.R.A.C.P.
Kelvin Chambers, The Terrace, Wellington, New Zealand.

Present Appointments:

Senior Neurologist, Wellington Hospital, N.Z.
Honorary Neurologist, Home of Compassion Hospital, Wellington, N.Z.

DR W. J. G. BURKE, M.B., B.S., M.R.C.P. (Lond.), M.R.A.C.P.
149 Macquarie Street, Sydney, N.S.W.

Present Appointments:

Honorary Neurologist, St. Vincent's Hospital, Sydney.
Honorary Consultant Neurologist, The Mater Hospital, Sydney.
Honorary Assistant Physician, Lewisham Hospital.
University Lecturer in Neuroanatomy and Clinical Neurology.

DR LEONARD B. COX, M.D., M.R.C.P. (Edin.), F.R.A.C.P. (Foundation Member)
421 St. Kilda Road, Melbourne, Vic.

Present Appointments:

Consulting Neurologist, Alfred Hospital, Melbourne.
Consulting Neurologist, Queen Victoria Hospital, Melbourne.

DR DAVID, R. CURTIS, M.B., B.S. Ph.D.
Department of Physiology, The Australian National University, Canberra, A.C.T.

Present Appointments:

Senior Fellow, Department of Physiology, Australian National University, Canberra.

DR ERIC L. DAVIS, M.B., B.S., M.R.C.P. (Edin.), M.R.A.C.P.
193 Macquarie Street, Sydney, N.S.W.

Present Appointments:

Hon. Asst. Electro-encephalographer and Hon. Assoc. Physician (Neurology), Royal North Shore Hospital, Sydney.
Consultant Neurologist, North Ryde Psychiatric Centre and N.S.W. State Mental Service.
Consultant Neurologist, the Spastic Centre, Sydney, and N.S.W. Society for Crippled Children.
Consultant Neurologist, Ryde District Hospital and Manly District Hospital.

DR PETER EBELING, B.Sc., M.D., M.R.C.P., M.R.A.C.P.
239 South Road, Brighton, Vic.

Present Appointments:

Asst. Neurologist, Royal Melbourne Hospital.
Asst. Neurologist, Royal Children's Hospital, Melbourne.
Hon. Visiting Neurologist, Geelong and District Hospital.
Visiting Specialist, Repatriation Department.
Electro-encephalographer, Royal Melbourne Hospital.
Hon. Neurologist, Preston and Northcote District Hospital.

DR ANTHONY GRAHAM FISHER, M.D., M.R.C.P., M.R.A.C.P.
1215 Hay Street, West Perth, W.A.

Present Appointments:

Hon. Asst. Neurologist, Royal Perth Hospital.
Hon. Visiting Consultant Neurologist, Princess Margaret Hospital for Children, Perth.
Hon. Consultant Neurologist, Sir James Mitchell Spastic Centre, Perth.
Visiting Specialist, Repatriation Commission, W.A. Branch.

DR GAVIN L. GLASGOW, M.B., Ch.B. (N.Z.), M.R.C.P., M.R.A.C.P.
17 Mount Street, Auckland, N.Z.

Present Appointments:

Part-time visiting Neurological Physician, Auckland Hospital, N.Z.

DR JOHN V. GORDON, M.D., M.R.C.P., F.R.A.C.P.
254 North Terrace, Adelaide, S.A.

Present Appointments:

Honorary Neurologist, Royal Adelaide Hospital.
Honorary Neurologist, Adelaide Children's Hospital.
Neurologist, Repatriation Department, S.A.

DR JAMES WALDO LANCE, M.D., M.R.C.P., M.R.A.C.P.
Department of Neurology, Prince Henry's Hospital, Sydney, N.S.W.

Present Appointments:

Honorary Asst. Physician, Sydney Hospital.
Honorary Asst. Physician, St. Luke's Hospital.
Honorary Physician, Northcott Neurological Centre.

DR P. J. LANDY, M.B., B.S., M.R.C.P.
79 Wickham Terrace, Brisbane, Qld.

Present Appointments:

Neurologist, Mater Hospital, Brisbane.
Neurologist, Repatriation Department, Queensland.
Neurologist, Brisbane Mental Hospital.
Electro-encephalographer, North Brisbane Hospital.
Junior Physician, South Brisbane Hospital.

PROFESSOR A. K. MCINTYRE, D.Sc., M.B., B.S.
Department of Physiology, Monash University, P.O. Box 92, Clayton, Vic.

Present Appointments:

Professor of Physiology, Monash University, Vic.

DR K. B. NOAD, M.D., F.R.C.P., P.R.A.C.P. (Foundation Member)
135 Macquarie Street, Sydney, N.S.W.

Present Appointments:

Honorary Consultant Physician, Sydney Hospital.
Honorary Director, Northcott Neurological Centre, North Sydney.

DR R. H. C. RISCHBIETH, M.B., B.S., M.R.C.P. (Lond.), M.R.C.P. (Edin.), M.R.A.C.P.
34 Church Terrace, Walkerville, S.A.

Present Appointments:

Neurologist, The Queen Elizabeth Hospital, Woodville.
Senior Neurological Registrar (part-time), Royal Adelaide Hospital.

DR ARTHUR C. SCHWIEGER, M.D., M.R.C.P., F.R.A.C.P.
33 Collins Street, Melbourne, C.1

Present Appointments:

Honorary Neurologist, Prince Henry's Hospital, Melbourne.
Asst. Honorary Neurologist, Royal Melbourne Hospital.
Visiting Neurologist, Repatriation Department.
Consultant Neurologist for Mental Hygiene Authority, Victoria, Footscray and District Hospital, and Box Hill and District Hospital.

PROFESSOR SYDNEY SUNDERLAND, C.M.G., D.Sc., M.D., B.S., F.R.A.C.P., F.R.A.C.S., F.A.A. (Foundation Member)
Anatomy Department, University of Melbourne, Carlton, Vic.

Present Appointments:

Professor of Experimental Neurology, Melbourne University.
Dean of the Faculty of Medicine, Melbourne University.

DR JOHN MACKAY SUTHERLAND, M.D., Ch.B. (Glasg.), F.R.C.P. (Edin.), M.R.A.C.P.
87 Wickham Terrace, Brisbane, Queensland.

Present Appointments:

Neurologist, Brisbane Hospital.
Neurologist, Brisbane Children's Hospital.
Honorary Neurologist, Spastic Centre, New Farm, Brisbane.

ASSOCIATE MEMBERS

DR ROSS MCD. ANDERSON, M.B., B.S., M.C.P.A.
Pathology Department, University of Melbourne, Carlton, Vic.

Present Appointments:

Senior Lecturer in Neuropathology, Melbourne University.
Assistant to Honorary Neurologist, Alfred Hospital, Melbourne.

DR ROSS DAVIS, B.Sc., M.B., B.S.
Cerebral Surgery and Research Unit, Callan Park, Rozelle, N.S.W.

Present Appointments:

Neurophysiologist, Cerebral Surgery and Research Unit, Callan Park.